

Multi-Rod Constructs Can Increase the Incidence of Iliac Screw Loosening after Surgery for Adult Spinal Deformity

Tomohiro Banno¹, Tomohiko Hasegawa¹, Yu Yamato¹, Daisuke Togawa¹, Go Yoshida¹, Sho Kobayashi², Tatsuya Yasuda¹, Hideyuki Arima¹, Shin Oe¹, Yuki Mihara¹, Hiroki Ushirozako¹, Yukihiro Matsuyama¹

¹Department of Orthopaedic Surgery, Hamamatsu University School of Medicine, Hamamatsu, Japan

²Department of Orthopaedic Surgery, Hamamatsu Medical Center, Hamamatsu, Japan

Study Design: A retrospective study.

Purpose: To investigate the incidence of iliac screw loosening with a two-rod vs. multi-rod construct and the effect on clinical and radiographic outcomes after surgery for adult spinal deformity (ASD).

Overview of Literature: Multi-rod construct is useful for preventing rod fracture in ASD surgery. However, limited information is available regarding the incidence of iliac screw loosening after corrective fusion surgery using a multi-rod construct.

Methods: Total 106 patients with ASD (24 men and 82 women; mean age, 68 years) who underwent corrective fusion surgery using bilateral iliac screws and were followed up for at least 1 year were reviewed. The following variables were compared between patients who underwent surgery with a two-rod and multi-rod construct: age, sex, bone mineral density (BMD), fusion level, high-grade osteotomy, L5/S interbody fusion, screw loosening (upper instrumented vertebra [UIV], S1, and iliac), rod fracture, proximal junctional kyphosis, spinopelvic parameters, and Oswestry Disability Index (ODI) score. We also compared patients with and without iliac screw loosening in the multi-rod construct group.

Results: Of the 106 patients, 55 underwent surgery with a conventional two-rod construct and 51 with a multi-rod construct (three rods in 16, four rods in 35). Iliac and UIV screw loosening was observed in 24 patients (21%) and 35 patients (33%), respectively. The multi-rod group showed significantly higher incidence of iliac and UIV screw loosening and lower incidence of rod fracture. Patients with iliac screw loosening had a lower BMD than those without screw loosening; however, no significant differences were observed in the spinopelvic parameters or the ODI score.

Conclusions: The use of multi-rod constructs led to a higher incidence of junctional screw loosening than the use of conventional two-rod constructs, especially in patients with osteoporosis. Iliac screw loosening did not affect sagittal alignment or clinical outcome in the short term.

Keywords: Adult spinal deformity; Complication; Iliac screw; Multi-rod construct; Screw loosening; Adult spinal deformity

Received Aug 15, 2018; Revised Oct 14, 2018; Accepted Oct 17, 2018

Corresponding author: Tomohiro Banno

Department of Orthopaedic Surgery, Hamamatsu University School of Medicine, 1-20-1 Handayama, Higashi-ku, Hamamatsu, Shizuoka 431-3192, Japan

Tel: +81-53-435-2299, Fax: +81-53-435-2296, E-mail: tomohiro.banno0311@gmail.com

Introduction

Patients with adult spinal deformity (ASD), especially the elderly patients, experience several symptoms that seriously compromise their quality of life. Several studies have proposed target values for corrective surgery, and many surgeons perform corrective surgery using a long construct and various osteotomies to achieve optimal alignment in patients with a severe deformity [1,2]. However, corrective surgery for ASD patients remains challenging owing to many perioperative complications and future reoperations [3,4].

Rod breakage is the most serious implant-related complication that leads to severe back pain, loss of correction, and need for revision surgery in most cases [5,6]. We previously reported 54 cases of rod fracture (18%) after corrective fusion surgery in 304 ASD patients, 36 (66.7%) of whom required revision surgery [7]. We have observed several cases of rod fracture; therefore, we decided to attach additional rods to the two main rods to prevent rod fracture after ASD surgery with pelvic fixation. Several authors also recommend multi-rod constructs for the prevention of rod fracture and pseudarthrosis [8-10]. However, the stronger construct seems to concentrate the mechanical force on the junctional segments, and limited information is available regarding the clinical effects of long-segment fusion using a multi-rod construct on such junctional segments.

We previously reported a relatively high incidence (28%) of iliac screw loosening after ASD surgery, with at least 2 years of follow-up [11]. Moreover, patients with iliac screw loosening showed worse sagittal alignment and clinical outcome than those without screw loosening. Thus, iliac screw loosening may be an indicator of distal junctional instability and poor prognosis.

To the best of our knowledge, this is the first study to compare the incidence of iliac screw loosening between patients who underwent surgery with a standard two-rod construct and those with a multi-rod construct; we also examined the influence of iliac screw loosening on clinical and radiographic outcomes after ASD surgery.

Materials and Methods

1. Patient enrollment

All study participants provided informed consent, and the

study design was approved by the appropriate ethics review boards in Hamamatsu University School of Medicine (research approval no., 14-306). ASD patients who underwent corrective fusion surgery using long constructs from the lower thoracic spine (T7–12) to the pelvis with bilateral iliac screws from April 2011 to February 2017 at our department with at least 1 year of follow-up were enrolled. We excluded patients who required more than two iliac screws and those with upper thoracic fusion or iliac screw misplacement that could influence iliac screw loosening.

2. Surgical procedure for iliac screw insertion

Surgeries were performed by one of six board-certified spine surgeons. We inserted iliac screws freehand from the posterior superior iliac spine (PSIS) without separate skin incision. The PSIS was exposed via periosteal dissection of the soft tissue, and the tips of the PSIS were removed using a rongeur. A blunt probe was gently and carefully inserted into the cancellous bone of the ilium, taking care to avoid penetration of the table. Lateral and sagittal angles of the screw were determined using preoperative computed tomography (CT) and intraoperative lateral spinopelvic radiography, respectively. A screw (7.5 mm in diameter and 75–80 mm in length) was adopted and commonly used. The screw was inserted to considerable depth to prevent a prominent screw head. All the patients underwent posterior bone grafting using local bone, with or without L5/S interbody fusion.

3. Rod construct

We attempted to place additional rods for posterior corrective fusion in 2013 after observing several cases of rod fractures in patients with the use of conventional two-rod constructs. The period from 2013–2015 was a transitional period, and the surgeon determined the type of rod construct after considering several factors, such as spinal stability, closure of the osteotomy site, bone fragility, and their own experience with rod fracture. From 2016, multi-rod constructs were used in all cases. Additional rods were constructed on the inside from one or both sides of a conventional rod using three or four side-by-side connectors. A commercially pure titanium rod ($\phi 6.0$ mm or $\phi 6.35$ mm) was mainly used for less mechanical stress and prevention of screw pulling out.

4. Clinical assessment

The following demographic and clinical data were extracted from medical records for retrospective analysis: age, sex, and bone mineral density (BMD) of the proximal femur assessed using dual-energy X-ray absorptiometry. Furthermore, the following operative data were extracted: upper instrumented vertebra (UIV), presence or absence of high-grade osteotomy (pedicle subtraction osteotomy [PSO] or vertebral column resection [VCR]), and enforcement of L5/S interbody fusion. The Oswestry Disability Index (ODI) score was assessed preoperatively and at the 1-year follow-up to determine the health-related quality of life.

5. Radiographic assessment

Iliac, S1, and UIV screw loosening was assessed using anteroposterior radiography at the 1-year follow-up. Screw loosening was defined as a circumferential radiolucent area ≥ 1 mm around the screw observed by more than two observers (Fig. 1) [12,13]. In case of any ambiguity, CT was used for determination of loosening. The incidence of rod fracture and proximal junctional kyphosis (PJK) was also assessed during the postoperative follow-up period. The following radiographic parameters were measured using whole-spine radiography preoperatively, early postoperatively, and 1-year postoperatively: sagittal vertical axis (SVA), T1-pelvic angle (TPA), pelvic tilt (PT), pelvic incidence (PI), L1–S1 lumbar lordosis (LL), and proximal junctional angle (PJA). Radiographic views were obtained

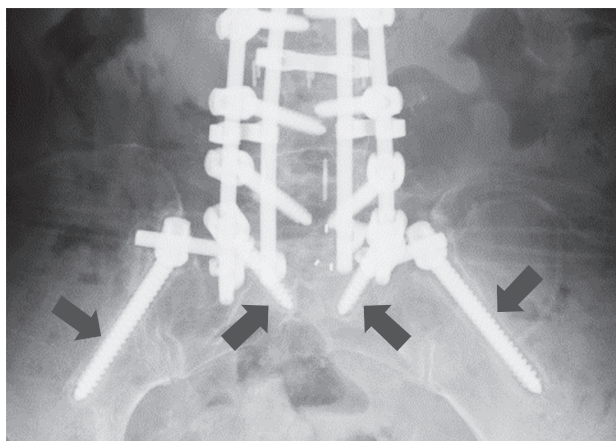


Fig. 1. Assessment of the radiolucent area around the screw as a typical radiographic sign of screw loosening (arrows).

with 1.5 m between the X-ray tube and the radiograph. A standing posture for lateral whole-spine radiography was standardized: subjects were asked to relax their heads while looking straight ahead, without pulling in the chin, and with their hands on their clavicle.

6. Statistical analyses

Patients were divided into two groups as per the type of rod construct used for them: conventional two-rod or multi-rod (three or four rods) (Fig. 2). Age, sex, BMD, fusion level, rate of high-grade osteotomy, rate of L5/S interbody fusion, rate of screw loosening (UIV, S1, and iliac), rate of rod fracture, spinopelvic parameters (SVA, PT, PI, LL, and PJA), and ODI score of the two groups were compared. Moreover, patients in the multi-rod group were divided into two groups as per the presence or absence of iliac screw loosening and compared. Student *t*-test, Mann–Whitney *U*-test, chi-square test, and Fisher's exact test were used to evaluate the differences between the groups. Moreover, factors that contributed to iliac screw loosening were calculated using logistic regression with age, sex, BMD, fusion level, presence of high-grade osteotomy, enforcement of L5/S interbody fusion, and rod number (two-rod or multi-rod) as explanatory variables, and the presence of iliac screw loosening as a free variable. A *p*-value < 0.05 was considered statistically significant. All statistical analyses were performed using IBM SPSS ver. 22.0 (IBM Corp., Armonk, NY, USA).

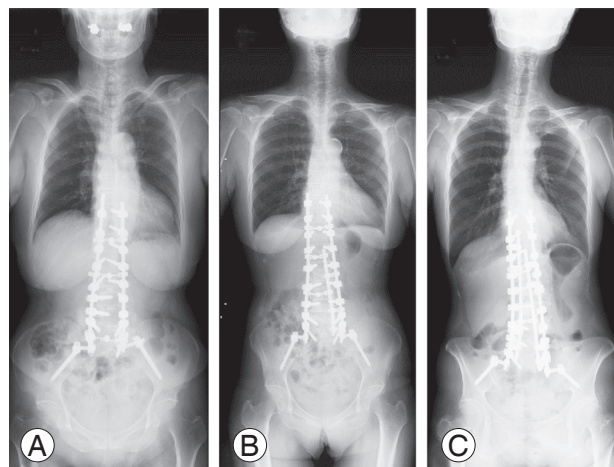


Fig. 2. Examples of rod constructs. (A) Two-rod construct. (B) Three-rod construct. (C) Four-rod construct.

Results

Among 460 eligible patients identified over the study period, 106 (24 men and 82 women; age range, 37–83 years; mean age, 68 years) were included. The mean follow-up period was 42 months (range, 13–83 months). Fifty-five patients underwent corrective fusion surgery using a conventional two-rod construct, while 51 patients underwent surgery with a multi-rod construct (three rods in 16 patients, four rods in 35 patients). BMD measurement was performed in 66 cases, with a mean T score at the femoral neck of -1.5 ± 1.1 . High-grade osteotomies were performed in 38 patients (PSO in 23 patients, VCR in 15 patients) [14]. The mean number of fused levels was 8.5 segments, with a UIV of T7 in four patients, T8 in 10 patients, T9 in 27 patients, T10 in 63 patients, T11 in one patient, and T12 in one patient. All the patients underwent sacroiliac fusion using bilateral S1 and iliac screws. L5/S interbody fusion was performed in 83 patients (78%). Iliac and UIV screw loosening was observed in 24 patients (21%) and 35 patients (33%), respectively. Among the 24 patients with

iliac screw loosening, seven (7%) also showed S1 screw loosening. During the follow-up, rod fracture and PJK occurred in 24 patients (21%) and 27 patients (25%), respectively (Table 1). Iliac screw removal was only required for one patient because of a prominent screw head, while none required revision surgery for L5/S pseudarthrosis. Sixteen patients underwent revision surgery; three because of PJK and 13 because of rod breakage.

Comparing the two-rod and multi-rod groups, the incidence of iliac screw loosening (37% versus 9%, $p < 0.001$) and UIV screw loosening (43% versus 23%, $p = 0.033$) was significantly higher in the multi-rod group. In contrast, the incidence of rod fracture was significantly lower in the multi-rod group (10% versus 35%, $p = 0.002$), while no intergroup differences were observed in terms of age, sex, BMD, fusion level, high-grade osteotomy, L5/S interbody fusion, or PJK (Table 1). Multiple logistic regression analysis indicated that BMD and multi-rod construct considerably affected the incidence of iliac screw loosening (odds ratio [OR], 2.6; 95% confidence interval [CI], 1.2–5.9; $p = 0.019$; and OR, 33.6; 95% CI, 3.4–329.3; $p = 0.003$, re-

Table 1. Comparison of demographic data between two-rod and multi-rod group

Characteristic	Total (N=106)	Two-rod (n=55)	Multi-rod (n=51)	p-value
Age (yr)	68.2±9.5	68.8±10.2	67.6±8.9	0.510
Sex				0.799
Male	24	13	11	
Female	82	42	40	
Bone mineral density (T-score)	-1.5±1.1	-1.8±1.2	-1.4±0.9	0.116
Fusion level	8.5±0.9	8.6±0.9	8.5±0.9	0.378
High grade osteotomies	38 (36)	21 (38)	17 (33)	0.603
L5/S interbody fusion	83 (78)	45 (82)	38 (75)	0.362
Screw loosening				
Upper instrumented vertebra	35 (33)	13 (23)	22 (43)	0.033
S1	7 (7)	2 (4)	5 (10)	0.258
Iliac	24 (21)	5 (9)	19 (37)	<0.001
Rod fracture	24 (21)	19 (35)	5 (10)	0.002
Proximal junctional kyphosis	27 (25)	16 (29)	11 (22)	0.374

Values are presented as mean±standard deviation, number, or number (%).

Table 2. Logistic regression assessing factors contributing to iliac screw loosening

	Regression coefficient (B)	Standard error of B	p-value	Odds ratio (95% confidence interval)
Bone mineral density	0.968	0.412	0.019	2.632 (1.17–5.90)
Multi rod	3.514	1.165	0.003	33.566 (3.42–329.3)

spectively), while age, sex, fusion level, high-grade osteotomies, and L5/S interbody fusion were not statistically associated with iliac screw loosening (Table 2).

Regarding spinopelvic parameters and ODI score, although these values were significantly improved postoperatively, no significant differences were observed between the two-rod and multi-rod groups at any time point (Table 3).

When patients in the multi-rod group were divided as per the presence of iliac screw loosening, those with screw loosening showed a lower BMD (T score: -1.9 versus -1.0, $p=0.005$), higher rate of a four-rod construct (44% versus 11%, $p=0.015$), UIV screw loosening (68% versus 28%, $p=0.005$), and S1 screw loosening (26% versus 0%, $p=0.005$); however, there were no significant differences in the age, sex, fusion level, high-grade osteotomy, L5/S interbody fusion, rod fracture, or PJK (Table 4). Furthermore, no significant intergroup differences were observed in the spinopelvic parameters or ODI at any time point

(Table 5). However, when the patient with and without S1 screw loosening were compared, those with screw loosening had significantly worse SVA and TPA at 1-year postoperatively (Table 6).

Discussion

To our knowledge, this is the first study to compare the incidence of iliac screw loosening between patients who underwent surgery with a standard two-rod construct versus those who underwent surgery with a multi-rod construct and evaluate the influence of iliac screw loosening on the clinical and radiographic outcomes following ASD surgery. Our findings revealed that the use of a multi-rod construct for long-segment fusion surgery is associated with a higher incidence of junctional screw loosening, especially in patients with osteoporosis. Furthermore, iliac screw loosening did not affect sagittal alignment or clinical outcomes in the short term.

Table 3. Comparison of spinopelvic parameters and ODI between two-rod and multi-rod group

Variable	Total	Two-rod	Multi-rod	<i>p</i> -value
Preoperative				
SVA (mm)	122.0±83.0	124.0±85.0	121.0±81.0	0.869
TPA (°)	38.3±15.0	37.8±15.9	38.9±13.9	0.711
PT (°)	35.1±10.6	33.3±11.2	37.1±9.6	0.065
PI-LL (°)	41.5±22.9	38.2±24.6	45.1±20.6	0.123
PJA (°)	3.8±6.5	4.4±6.7	3.1±6.2	0.303
Postoperative				
SVA (mm)	32.0±42.0	31.0±44.0	34.0±40.0	0.752
TPA (°)	17.2±8.2	16.3±8.8	18.1±7.9	0.256
PT (°)	20.1±8.6	19.0±8.8	21.2±8.3	0.204
PI-LL (°)	6.5±12.3	4.6±12.2	8.1±12.2	0.151
PJA (°)	11.9±7.7	12.2±7.2	11.4±8.3	0.595
1 Year postoperative				
SVA (mm)	44.5±47.0	41.0±43.0	48.0±51.0	0.406
TPA (°)	21.2±9.7	19.6±9.7	22.8±9.7	0.093
PT (°)	24.1±8.9	22.9±9.2	25.3±8.6	0.169
PI-LL (°)	9.8±15.1	7.1±16.4	12.6±13.3	0.064
PJA (°)	17.0±10.5	17.8±10.6	16.1±10.5	0.433
ODI preoperative	42.3±15.0	44.2±15.1	40.2±14.7	0.169
ODI 1 year postoperative	27.7±17.9	28.5±19.3	26.8±16.3	0.634

Values are presented as mean±standard deviation.

ODI, Oswestry Disability Index; SVA, sagittal vertical axis; TPA, T1-pelvic angle; PT, pelvic tilt; PI, pelvic incidence; LL, lumbar lordosis; PJA, proximal junctional angle.

Table 4. Comparison of demographic data between with and without iliac screw loosening in multi-rod group

Variable	Iliac screw loosening		<i>p</i> -value
	Yes (n=19)	No (n=32)	
Age (yr)	68.8±8.4	66.9±9.2	0.463
Sex			0.841
Male	4	6	
Female	15	26	
Bone mineral density (T-score)	-1.9±0.9	-1.0±0.8	0.005
Fusion level	8.5±1.1	8.4±0.8	0.642
High grade osteotomies	8 (42)	8 (25)	0.203
L5/S interbody fusion	14 (74)	23 (74)	0.889
Rod			0.015
Three rods	2	14	
Four rods	17	18	
Screw loosening			
Upper instrumented vertebra	13 (68)	9 (28)	0.005
S1	5 (26)	0	0.005
Rod fracture	3 (16)	2 (6)	0.348
Proximal junctional kyphosis	5 (26)	6 (19)	0.525

Values are presented as mean±standard deviation, number, or number (%).

In ASD patients, aggravation of clinical symptoms is specifically associated with loss of sagittal alignment. Thus, a principal goal of corrective surgery is the restoration of proper sagittal spinopelvic alignment using rigid instrumented fixation [1,15,16]. In patients with severe rigid spinal deformity, several osteotomies and a long construct are useful for the restoration of spinal alignment and improvement in clinical outcomes. However, these procedures and greater correction of spinal alignment cause mechanical stress on the construct and involve the risk of rod fracture [17]. Multi-rod constructs are reportedly useful in preventing rod fracture [8-10]. Kelly et al. [10] compared a four-rod and a conventional two-rod construct for lumbopelvic fixation in a biomechanical study. They revealed that the four-rod construct provided significantly greater fixation stability than the conventional two-rod construct. Clinically, Hyun et al. [8] compared the radiographic outcomes using a standard two-rod and a multi-rod construct across three-column osteotomy sites in a matched cohort. The use of a multi-rod construct provided increased stability and was significantly more efficient in preventing implant failure and symptomatic pseudarthrosis as compared to a standard two-rod construct. In our study, consistent with previous reports, the

multi-rod group showed a significantly lower incidence of rod fracture than the two-rod group. In contrast, the multi-rod group showed a higher incidence of iliac screw loosening although there were no intergroup differences in the reported risk factors for iliac screw loosening: BMD, fusion level, high-grade osteotomy, L5/S interbody fusion, and spinopelvic parameters [11,18,19] (Tables 1, 3). Moreover, using multiple regression analysis, we found that the use of the multi-rod construct had the greatest effect on iliac screw loosening (Table 2). These results indicate that stronger fixation by a multi-rod construct can cause concentration of mechanical stress on the distal junctional segments. Considering that no revision surgery was required for iliac screw loosening and that there is a high revision rate (54%) for rod fracture in patients with corrective fusion using iliac screw fixation, it is preferable to use multi-rod constructs for reducing the need for revision surgery. Moreover, for the proximal junctional segments, the multi-rod group had a higher incidence of UIV screw loosening, although no intergroup differences were observed in PJK or PJA. This suggests that the multi-rod construct did not contribute to PJK development. The causes of PJK are not fully understood and are reported to be multifactorial [20]; further, UIV screw loosening may

Table 5. Comparison of spinopelvic parameters and ODI between with and without iliac screw loosening in multi-rod group

Variable	Iliac screw loosening		p-value
	Yes	No	
Preoperative			
SVA (mm)	136.0±100.0	111.0±66.0	0.299
TPA (°)	41.4±15.0	37.4±13.2	0.326
PT (°)	38.3±11.2	36.4±8.7	0.511
PI-LL (°)	48.6±23.1	43.0±19.0	0.357
PJA (°)	1.9±6.4	3.8±6.1	0.305
Postoperative			
SVA (mm)	32.0±35.0	34.0±43.0	0.836
TPA (°)	19.4±7.8	17.4±8.0	0.396
PT (°)	22.2±7.9	20.6±8.6	0.510
PI-LL (°)	6.3±13.8	9.1±11.3	0.438
PJA (°)	13.3±9.8	10.3±7.3	0.225
1 Year postoperative			
SVA (mm)	61.0±58.0	41.0±45.0	0.162
TPA (°)	25.6±10.5	21.1±8.9	0.112
PT (°)	26.8±9.8	24.5±7.8	0.355
PI-LL (°)	13.6±15.5	12.1±12.2	0.718
PJA (°)	14.7±9.7	17.1±11.0	0.440
ODI preoperative	41.3±15.4	39.5±14.5	0.163
ODI 1 year postoperative	27.4±16.6	26.4±16.3	0.617

Values are presented as mean±standard deviation.

ODI, Oswestry Disability Index; SVA, sagittal vertical axis; TPA, T1-pelvic angle; PT, pelvic tilt; PI, pelvic incidence; LL, lumbar lordosis; PJA, proximal junctional angle.

not be a risk factor.

Patients with screw loosening had a significantly lower BMD, higher rate of a four-rod construct, and higher prevalence of UIV and S1 screw loosening (Table 4). Many of our elderly ASD patients also had osteoporosis. Implant-related complications and adjacent vertebral fracture frequently occur in osteoporosis patients [21,22]. Osteoporosis has also been reported as a risk factor for pedicle screw loosening [18,19]. In a biomechanical study, Weiser et al. [23] showed that pedicle screw stability is highly correlated with BMD. Therefore, patients with severe osteoporosis are at a higher risk of screw loosening when they undergo corrective fusion surgery using a multi-rod construct.

Regarding screw loosening, some authors have reported that screws with radiolucent areas are indicators of in-

Table 6. Comparison of spinopelvic parameters and ODI between with and without S1 screw loosening in multi-rods group

Variable	S1 screw loosening		p-value
	Yes (n=5)	No (n=46)	
Preoperative			
SVA (mm)	125.0±102.0	120.0±80.0	0.890
TPA (°)	38.6±19.7	38.9±13.4	0.966
PT (°)	35.2±15.8	37.3±9.0	0.511
PI-LL (°)	39.4±23.6	45.7±20.4	0.519
PJA (°)	0.6±8.1	3.4±6.0	0.345
Postoperative			
SVA (mm)	52.0±15.0	32.0±41.0	0.354
TPA (°)	23.5±11.5	17.6±7.5	0.156
PT (°)	24.0±13.2	20.9±7.9	0.485
PI-LL (°)	12.3±20.0	7.7±11.6	0.483
PJA (°)	20.3±14.3	10.6±7.3	0.025
1 Year postoperative			
SVA (mm)	115.0±62.0	41.0±45.0	0.001
TPA (°)	31.4±16.1	21.9±8.4	0.034
PT (°)	27.2±16.2	25.1±7.6	0.613
PI-LL (°)	16.8±21.8	12.2±12.3	0.466
PJA (°)	23.6±9.7	15.4±10.1	0.097
ODI preoperative	42.6±14.0	40.8±16.4	0.700
ODI 1 year postoperative	21.6±13.6	29.7±17.6	0.457

Values are presented as mean±standard deviation.

ODI, Oswestry Disability Index; SVA, sagittal vertical axis; TPA, T1-pelvic angle; PT, pelvic tilt; PI, pelvic incidence; LL, lumbar lordosis; PJA, proximal junctional angle.

stability and influence the achievement of solid fusion [12,13]. However, in terms of iliac screws, screw loosening itself does not necessary indicate instability of the lumbosacral junction because the sacroiliac joint exists between the iliac and S1 screws. In fact, we found no significant influence of iliac screw loosening on postoperative spinopelvic parameters or the ODI score in the present study (Table 5). Previously, we investigated iliac screw loosening after corrective fusion surgery in 72 patients to find that those with iliac screw loosening for >2 years had worse sagittal alignment and ODI score than those without iliac screw loosening [11]. However, the short follow-up pe-

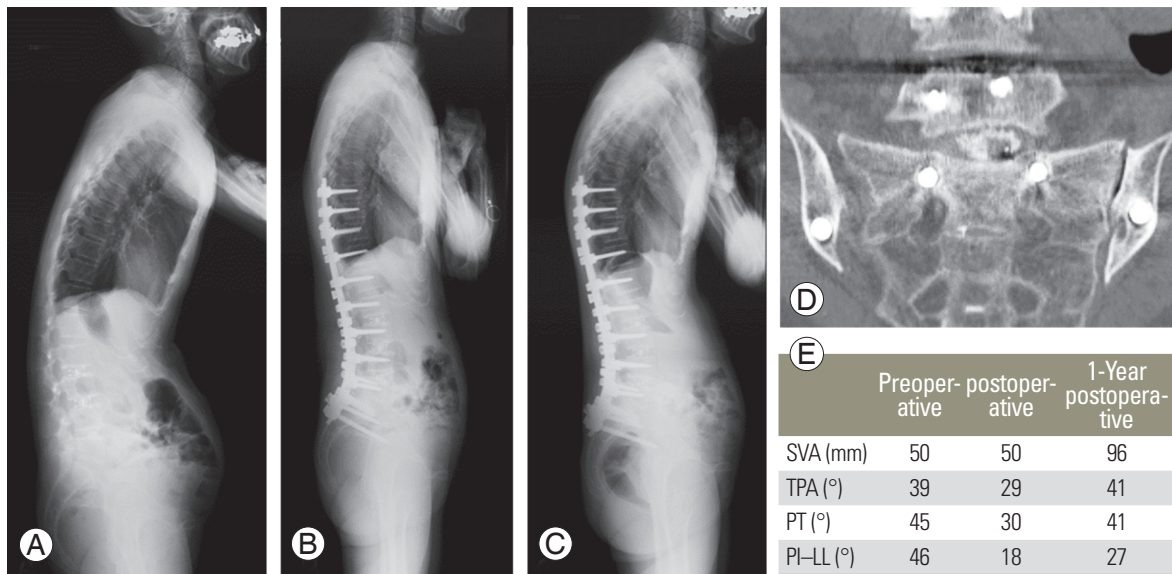


Fig. 3. Representative case of iliac and S1 screw loosening. Preoperative (A), early postoperative (B), and 1-year postoperative (C) whole spine radiographs with a correction loss following corrective fusion surgery. Postoperative computed tomography showed loosening of the S1 and iliac screws with L5/S non-union (D). (E) Time course change in the spinopelvic parameters. This patient showed postoperative correction loss. SVA, sagittal vertical axis; TPA, T1-pelvic angle; PT, pelvic tilt; PI, pelvic incidence; LL, lumbar lordosis.

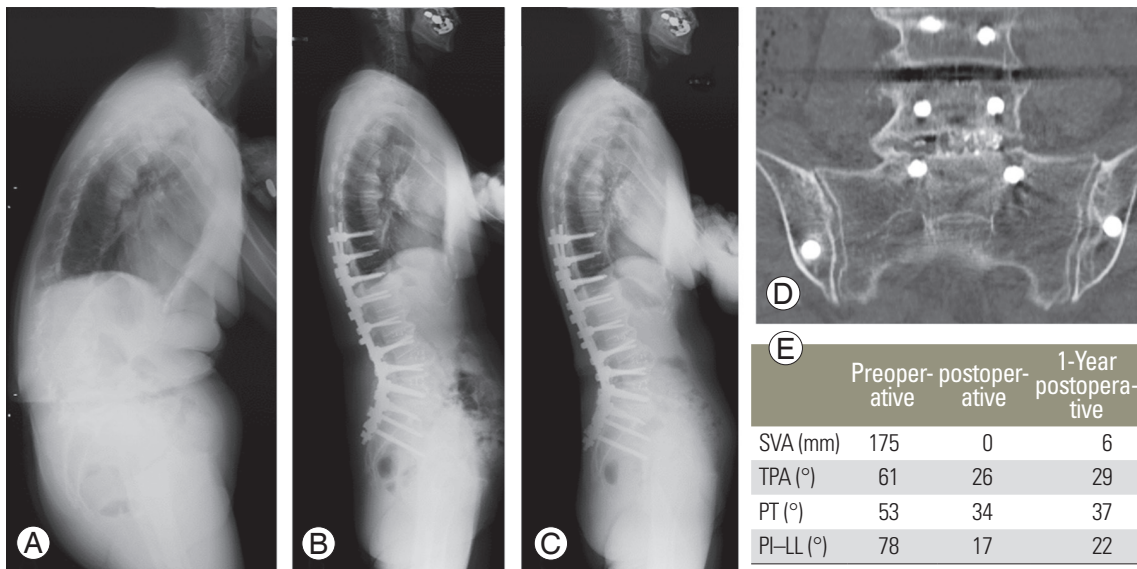


Fig. 4. Representative case of non-iliac screw loosening. Preoperative (A), early postoperative (B) and 1-year postoperative (C) whole spine radiographs with maintenance of sagittal alignment after corrective fusion surgery. Postoperative CT showed non-loosening of the S1 and iliac screws with L5/S fusion (D). (E) Time course change in the spinopelvic parameters. Sagittal alignment was maintained in this patient. SVA, sagittal vertical axis; TPA, T1-pelvic angle; PT, pelvic tilt; PI, pelvic incidence; LL, lumbar lordosis.

riod (1 year) and relatively small number of study subjects in the present study may be the reason for the different results. However, patients with both, iliac and S1 screw loosening had significantly worse SVA and TPA at 1 year postoperatively, indicating high instability of the lumbosacral junction and possible pseudarthrosis (Figs. 3, 4).

In order to lower the risk of screw loosening, surgeons should consider treatment of perioperative osteoporosis. Ohtori et al. [19] reported that teriparatide therapy significantly decreased the rate of pedicle screw loosening in osteoporosis patients. Moreover, to improve the anchoring strength of iliac screws, dual-screw placement or poly-

methylmethacrylate augmentation should be considered in osteoporosis patients [24,25]. Recently, the S2 alar iliac (S2AI) screw that can provide durable distal fixation with a low-profile, in-line technique, has been widely used, instead of a conventional iliac screw, for rigid lumbosacral fixation [26]. Screw head prominence is a major complication of iliac screws and frequently leads to severe pain, requiring screw removal. The incidence of iliac screw removal due to screw head prominence is reported to range from 6.1% to 34% [27-29]. However, in this study, screw removal was only required in one case (0.9%) for a prominent screw head, indicating a relatively low rate. We can prevent screw head prominence by attempting to place the iliac screw deep enough to hide the screw head below the iliac crest. However, screw breakage has been reported with the S2AI screw [30]. The S2AI screw penetrates the sacroiliac joint; therefore, mechanical stress might be concentrated on the screw. Once screw breakage occurs, revision surgery becomes challenging. Thus, we prefer to use iliac screws rather than S2AI screw.

This study has certain limitations. First, this study was designed retrospectively. Therefore, the follow-up period was different between the two-rod and multi-rod groups. Lertudomphonwanit et al. [6] investigated 526 patients who underwent corrective fusion surgery for ASD and reported that rod fracture occurred in 97 patients (18.4%). Among them, approximately 50% of rod fractures occurred more than 3 years postoperatively. Moreover, the long-term effect of iliac screw loosening on the distal junction is relatively unknown. Therefore, a long-term follow-up study is necessary on patients with a multi-rod construct. Second, our study did not perform bone union assessment. It is unclear whether iliac screw loosening was related to pseudarthrosis progression because we could not directly assess the presence of pseudarthrosis. However, five cases with S1 screw loosening involved significant deterioration of the SVA during the follow-up period, while iliac screw loosening alone did not affect postoperative alignment. These results suggest that S1 and iliac screw loosening together indicate distal junctional failure. Therefore, patients with iliac screw loosening should be provided treatment with care, with a special focus on the appearance of S1 screw loosening.

Conclusions

The use of a multi-rod construct for long-segment fusion

surgery was associated with a higher incidence of iliac screw loosening than the use of a conventional two-rod construct, especially in patients with osteoporosis. Iliac screw loosening did not affect sagittal alignment or clinical outcomes in the short term.

Conflict of Interest

No potential conflict of interest relevant to this article was reported. TB, HA, TH, YY, GY, SK, TY, YM, HU, and YM have nothing to disclose. DT and SO belong to the division as follows: Donated Fund Laboratory (Division of Geriatric Musculoskeletal Health, Hamamatsu University School of Medicine, Shizuoka, Japan); Meitoku Medical Institute Jyuzen Memorial Hospital, Shizuoka, Japan; Japan Medical Dynamic Marketing Inc., Tokyo, Japan; and Medtronic Sofamor Danek Inc., Memphis, TN, USA.

Author Contributions

Substantial contributions to the conception or design of the work: TB, TH, YY, DT, GY, SK, TY, HA, SO, YM, HU; acquisition, analysis, or interpretation of data for the work: TB, TH, YY, DT, GY, SK, TY, HA, SO, YM, HU; drafting the work or revising it critically for important intellectual content: TB, TH, YY, DT, GY, SK, TY, YM; and final approval of the version to be published: TB, YM

References

- Schwab F, Patel A, Ungar B, Farcy JP, Lafage V. Adult spinal deformity-postoperative standing imbalance: how much can you tolerate?: an overview of key parameters in assessing alignment and planning corrective surgery. *Spine* 2010;35:2224-31.
- Yamato Y, Hasegawa T, Kobayashi S, et al. Calculation of the target lumbar lordosis angle for restoring an optimal pelvic tilt in elderly patients with adult spinal deformity. *Spine* 2016;41:E211-7.
- Schwab FJ, Hawkinson N, Lafage V, et al. Risk factors for major peri-operative complications in adult spinal deformity surgery: a multi-center review of 953 consecutive patients. *Eur Spine J* 2012;21:2603-10.
- Yamato Y, Matsuyama Y, Hasegawa K, et al. A Japanese nationwide multicenter survey on perioperative complications of corrective fusion for elderly patients with adult spinal deformity. *J Orthop Sci*

- 2017;22:237-42.
5. Smith JS, Shaffrey CI, Ames CP, et al. Assessment of symptomatic rod fracture after posterior instrumented fusion for adult spinal deformity. *Neurosurgery* 2012;71:862-7.
 6. Lertudomphonwanit T, Kelly MP, Bridwell KH, et al. Rod fracture in adult spinal deformity surgery fused to the sacrum: prevalence, risk factors, and impact on health-related quality of life in 526 patients. *Spine J* 2018;18:1612-24.
 7. Yamato Y, Hasegawa T, Kobayashi S, et al. Treatment strategy for rod fractures following corrective fusion surgery in adult spinal deformity depends on symptoms and local alignment change. *J Neurosurg Spine* 2018;29:59-67.
 8. Hyun SJ, Lenke LG, Kim YC, Koester LA, Blanke KM. Comparison of standard 2-rod constructs to multiple-rod constructs for fixation across 3-column spinal osteotomies. *Spine* 2014;39:1899-904.
 9. Merrill RK, Kim JS, Leven DM, Kim JH, Cho SK. Multi-rod constructs can prevent rod breakage and pseudarthrosis at the lumbosacral junction in adult spinal deformity. *Global Spine J* 2017;7:514-20.
 10. Kelly BP, Shen FH, Schwab JS, Arlet V, Diangelo DJ. Biomechanical testing of a novel four-rod technique for lumbo-pelvic reconstruction. *Spine* 2008;33:E400-6.
 11. Banno T, Hasegawa T, Yamato Y, et al. Prevalence and risk factors of iliac screw loosening after adult spinal deformity surgery. *Spine* 2017;42:E1024-30.
 12. Sanden B, Olerud C, Petren-Mallmin M, Johansson C, Larsson S. The significance of radiolucent zones surrounding pedicle screws: definition of screw loosening in spinal instrumentation. *J Bone Joint Surg Br* 2004;86:457-61.
 13. Tokuhashi Y, Matsuzaki H, Oda H, Uei H. Clinical course and significance of the clear zone around the pedicle screws in the lumbar degenerative disease. *Spine* 2008;33:903-8.
 14. Schwab F, Blondel B, Chay E, et al. The comprehensive anatomical spinal osteotomy classification. *Neurosurgery* 2014;74:112-20.
 15. Schwab F, Ungar B, Blondel B, et al. Scoliosis Research Society-Schwab adult spinal deformity classification: a validation study. *Spine* 2012;37:1077-82.
 16. Lafage V, Schwab F, Patel A, Hawkinson N, Farcy JP. Pelvic tilt and truncal inclination: two key radiographic parameters in the setting of adults with spinal deformity. *Spine* 2009;34:E599-606.
 17. Smith JS, Shaffrey E, Klineberg E, et al. Prospective multicenter assessment of risk factors for rod fracture following surgery for adult spinal deformity. *J Neurosurg Spine* 2014;21:994-1003.
 18. Kim JB, Park SW, Lee YS, Nam TK, Park YS, Kim YB. The effects of spinopelvic parameters and paraspinal muscle degeneration on S1 screw loosening. *J Korean Neurosurg Soc* 2015;58:357-62.
 19. Ohtori S, Inoue G, Orita S, et al. Comparison of teriparatide and bisphosphonate treatment to reduce pedicle screw loosening after lumbar spinal fusion surgery in postmenopausal women with osteoporosis from a bone quality perspective. *Spine* 2013;38:E487-92.
 20. Lau D, Clark AJ, Scheer JK, et al. Proximal junctional kyphosis and failure after spinal deformity surgery: a systematic review of the literature as a background to classification development. *Spine* 2014;39:2093-102.
 21. Kwon BK, Elgafy H, Keynan O, et al. Progressive junctional kyphosis at the caudal end of lumbar instrumented fusion: etiology, predictors, and treatment. *Spine* 2006;31:1943-51.
 22. Seki S, Hirano N, Kawaguchi Y, et al. Teriparatide versus low-dose bisphosphonates before and after surgery for adult spinal deformity in female Japanese patients with osteoporosis. *Eur Spine J* 2017;26:2121-7.
 23. Weiser L, Huber G, Sellenschloh K, et al. Insufficient stability of pedicle screws in osteoporotic vertebrae: biomechanical correlation of bone mineral density and pedicle screw fixation strength. *Eur Spine J* 2017;26:2891-7.
 24. Zheng ZM, Zhang KB, Zhang JF, Yu BS, Liu H, Zhuang XM. The effect of screw length and bone cement augmentation on the fixation strength of iliac screws: a biomechanical study. *J Spinal Disord Tech* 2009;22:545-50.
 25. Yu BS, Zhuang XM, Zheng ZM, Li ZM, Wang TP, Lu WW. Biomechanical advantages of dual over single iliac screws in lumbo-iliac fixation construct. *Eur Spine J* 2010;19:1121-8.
 26. Chang TL, Sponseller PD, Kebaish KM, Fishman EK. Low profile pelvic fixation: anatomic parameters for sacral alar-iliac fixation versus traditional iliac fixation. *Spine* 2009;34:436-40.

27. Emami A, Deviren V, Berven S, Smith JA, Hu SS, Bradford DS. Outcome and complications of long fusions to the sacrum in adult spine deformity: luque-galveston, combined iliac and sacral screws, and sacral fixation. *Spine* 2002;27:776-86.
28. Tsuchiya K, Bridwell KH, Kuklo TR, Lenke LG, Baldus C. Minimum 5-year analysis of L5-S1 fusion using sacropelvic fixation (bilateral S1 and iliac screws) for spinal deformity. *Spine* 2006;31:303-8.
29. Cho W, Mason JR, Smith JS, et al. Failure of lumbopelvic fixation after long construct fusions in patients with adult spinal deformity: clinical and radiographic risk factors: clinical article. *J Neurosurg Spine* 2013;19:445-53.
30. Guler UO, Cetin E, Yaman O, et al. Sacropelvic fixation in adult spinal deformity (ASD); a very high rate of mechanical failure. *Eur Spine J* 2015;24:1085-91.