



Foramen Magnum Decompression with Outer Dura Matter Layer Resection for Chiari Type I Malformation: Factors Correlated with Syrinx Reduction

Toshiaki Maruyama¹, Toshio Nakamae¹, Naosuke Kamei¹,
Nobuhiro Tanaka², Yasushi Fujiwara³, Takahiro Harada¹, Nobuo Adachi¹

¹Department of Orthopaedic Surgery, Graduate School of Biomedical and Health Sciences, Hiroshima University, Hiroshima, Japan

²Department of Orthopaedic Surgery, JR Hiroshima Hospital, Hiroshima, Japan

³Department of Orthopaedic Surgery, Hiroshima City Asa Hospital, Hiroshima, Japan

Study Design: A retrospective cohort study.

Purpose: We aimed to investigate the surgical results of foramen magnum decompression (FMD) to identify the potential factors associated with syrinx reduction in Chiari malformation type I (CMI).

Overview of Literature: The predictive value of preoperative factors for syrinx reduction in patients with CMI remains debatable.

Methods: We enrolled patients who underwent microscopic FMD with outer dural layer resection for CMI. The distance from the tip of the cerebellar tonsil to the C2 vertebral endplate on sagittal magnetic resonance imaging (MRI) was defined as the tonsillar distance (TD). Patients who showed a >20% syrinx diameter reduction on the 1-year follow-up MRI were defined as the syrinx reduction group while the others were categorized in the syrinx nonreduction group. Patients with syringomyelia were categorized into the clinically improved and unimproved groups using the Chicago Chiari Outcome Scale. The imaging and clinical parameters were evaluated pre- and postoperatively.

Results: This study included 25 patients of whom 19 (76.0%) had syringomyelia. At the 1-year follow-up, the syrinx diameter had decreased in 11 patients (57.8%). The increased TD significantly differed between the syrinx reduction and nonreduction groups. At the 1-year follow-up, 12 and seven patients with syringomyelia were categorized into the clinically improved and unimproved groups, respectively. The clinically improved and unimproved groups showed significant differences in the mean age and increased TD.

Conclusions: Postoperative syrinx reduction was significantly correlated with the upward shifting of the cerebellar tonsil in patients with CMI. Our quantitative evaluation of the alterations in hindbrain position after FMD was easily performed and reflects the clinical outcomes.

Keywords: Chiari malformation type I; Foramen magnum decompression; Syrinx; Surgery; Tonsillar distance

Received Jan 8, 2022; Revised Mar 12, 2022; Accepted Mar 29, 2022

Corresponding author: Toshio Nakamae

Department of Orthopaedic Surgery, Graduate School of Biomedical and Health Sciences, Hiroshima University, 1-2-3 Kasumi, Minami-ku, Hiroshima, 734-8551, Japan

Tel: +81-82-257-5232, Fax: +81-82-257-5234, E-mail: nakamaet@hiroshima-u.ac.jp

Introduction

Chiari malformation type I (CMI) is characterized by cerebellar tonsillar herniation through the foramen magnum, which is associated with an abnormal posterior fossa constitution [1-4]. This condition may result in syringomyelia because of subarachnoid space obstruction and cerebrospinal fluid (CSF) flow disturbance at the foramen magnum level [2,5,6]. Foramen magnum decompression (FMD) has been usually performed to relieve compression and restore normal CSF pathways at the craniocervical junction [7-11]. Some studies have reported good results ranging from obvious reduction to complete syrinx resolution after FMD [9,10,12], whereas others have described a persistent or even deteriorative syrinx after FMD [13-15].

Several preoperative factors, including sex, age, cerebellar tonsil descent degree, and preoperative syrinx size and length, have been investigated to explore their correlations with syrinx reduction following FMD [9,10,12,16]. However, the predictive value of these factors for syrinx reduction remains debatable. The alterations of hindbrain position and morphology after FMD also provided clues regarding the relationship between the hindbrain shifting and syrinx resolution after FMD. Therefore, we retrospectively investigated the surgical results of FMD by evaluating the hindbrain position alterations and attempted to identify the potential factors associated with syrinx reduction in CMI.

Materials and Methods

1. Patients

We enrolled consecutive patients who underwent microscopic FMD with outer dural layer resection at Hiroshima University Hospital and Hiroshima City Asa Hospital between October 2005 and April 2016 for CMI. Inclusion criteria were as follows: (1) follow-up assessments were performed for >1 year, (2) preoperative and follow-up magnetic resonance imaging (MRI) was performed 1 year postoperatively, and (3) the presence of symptoms related to CMI. Patients with syringomyelia associated with other diseases, such as spinal cord tumors and adhesive arachnoiditis, or those with spinal cord injuries were excluded from this study. This study was approved by the institutional review board of Hiroshima University (approval no. E-1960) and all patients provided informed consent.

2. Surgical procedure

All surgical procedures were performed in the prone position. Under general anesthesia, midline incisions extending from the inion to the upper cervical spine were performed in all patients. After a standard 4-cm-wide, 3-cm-high craniectomy of the squamous part of the occipital bone above the foramen magnum, the C1 posterior arch was resected. All patients underwent FMD combined with resection of the C1 posterior arch and outer dura mater layer, which was advocated by Isu et al. [5]. In our series, the outer dura mater layer was incised in a cross shape (Supplement 1). All patients underwent routine motor-evoked potential monitoring using transcranial electrical stimulation throughout the surgery. We used intraoperative ultrasound to observe the CSF outflow at the craniocervical junction and determine the adequacy of decompression.

3. Clinical and radiologic evaluation

CMI was diagnosed when the cerebellar tonsil descended >5 mm below the foramen magnum on midline sagittal slices on MRI [17]. We defined the distance from the tip of the cerebellar tonsil to the C2 vertebral endplate as the tonsillar distance (TD) on a T2-weighted sagittal MRI. A tonsillar herniation reduction was defined as an increased distance between the pre- and postoperative TD to calculate the changes in the hindbrain position (Fig. 1A, B). The maximal anteroposterior diameter of the syrinx and the syrinx length (defined as the number of vertebral segments spanned by the syrinx) were measured on T2-weighted axial and sagittal MRI, respectively, to evaluate the severity of the syrinx (Fig. 2A, B) [18]. These parameters were evaluated preoperatively, at 1 year postoperatively, and at a final follow-up. Patients who showed a reduction of >20% in the maximal syrinx diameter at the 1-year follow-up MRI have constituted the syrinx reduction group while the others were categorized in the syrinx nonreduction group (Fig. 3A-D) [10].

The clinical results were assessed using the Chicago Chiari Outcome Scale (CCOS) [19]. The CCOS is composed of four categories as follows: pain, nonpain symptoms, functionality, and complications. The patient is assigned a score of 1-4 in each category for a total score of 4-16, with higher numbers representing better outcomes. Each patient with syringomyelia was divided into

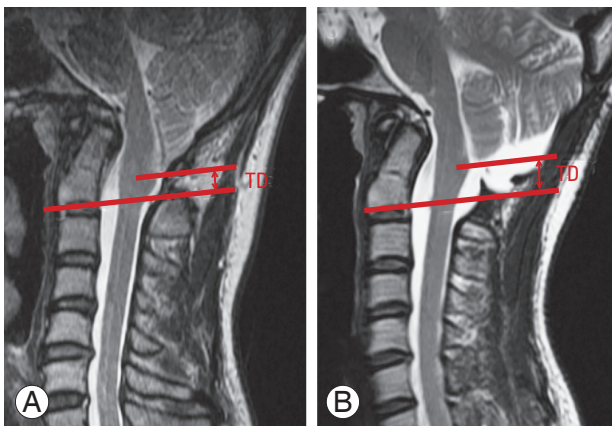


Fig. 1. Tonsillar distance (TD): the distance from the tip of the cerebellar tonsil to the C2 vertebral endplate on T2-weighted sagittal magnetic resonance imaging. A tonsillar herniation reduction was defined as an increase of the distance between preoperative TD (A) and postoperative TD (B).

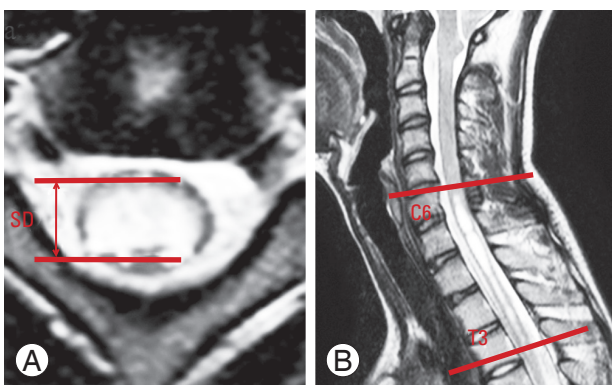


Fig. 2. Features of the syrinx on T2-weighted magnetic resonance imaging: maximal syrinx diameter (A) and syrinx length (B) (A) Axial; (B) sagittal. SD, maximum syrinx diameter.

the postoperative clinically improved group (CCOS score: 13–16) or the clinically unimproved group (CCOS score: 4–12) based on the calculated total CCOS scores [20].

The following parameters were evaluated in all patients and compared between the syrinx reduction and nonreduction groups as well as the clinically improved and unimproved groups: age upon surgery, syrinx length, preoperative coronal Cobb angle, CCOS, maximum syrinx diameter, syrinx diameter reduction, TD, increased TD, C2–C7 sagittal Cobb angle, basal and clivo-axial angles, Wiesel-Rothman interval, basion-axial interval, and atlas-to-dens interval (ADI).

4. Statistical analysis

Values are presented as mean±standard deviation. Statisti-

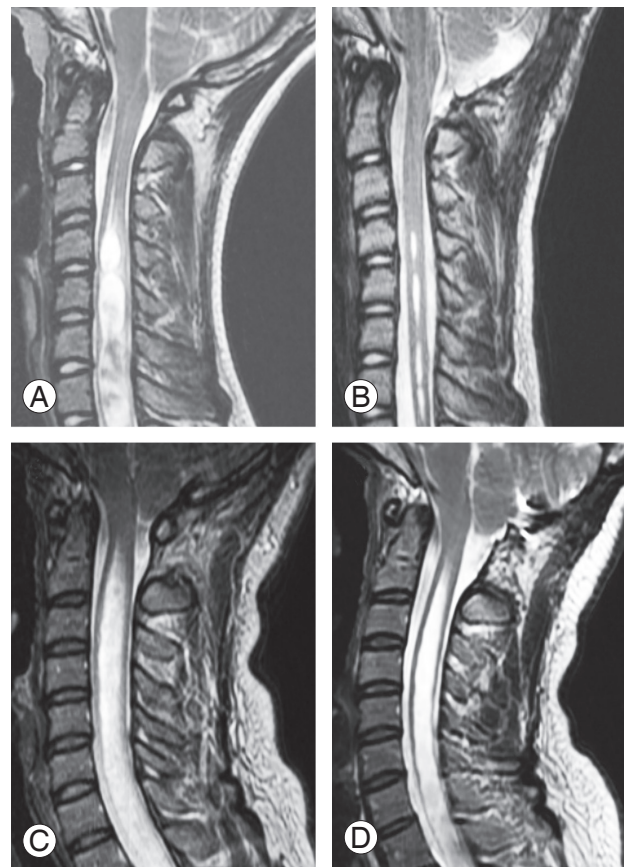


Fig. 3. Representative pre- (A, C) and postoperative (B, D) T2-weighted sagittal magnetic resonance imaging (MRI) from patients in the syrinx reduction group (A, B) and nonreduction group (C, D). Patients who showed a reduction of more than 20% in the maximal syrinx diameter at the 1-year follow-up MRI constituted the syrinx reduction group (A, B) while the others were categorized in the syrinx nonreduction group (C, D).

cal analysis was performed using the IBM SPSS statistical software package ver. 27.0.0 (IBM Corp., Armonk, NY, USA). The Mann-Whitney *U* test was used to compare data between groups. Statistical significance was defined as a probability value of <0.05.

Results

1. Overall outcomes

This study enrolled 25 patients (nine males and 16 females), with the mean age upon surgery and the mean duration of follow-up of 26.4±18.1 years (range, 3–66 years) and 59.0±40.0 months (range, 12–132 months), respectively. Syringomyelia was determined in 19 patients (76.0%) and scoliosis in 17 (68.0%). The mean syrinx length was 12.1±4.5, while the preoperative coronal Cobb angle was 22.7°±14.8°.

CSF leakage after surgery was found in one patient (4.0%), while none showed wound infection, neurological deficits, or vascular complications. The CSF leakage improved with conservative treatment. The mean CCOS score of our patients was 13.48 ± 1.73 , and the clinical improvement rate was 68.0% (17 patients). The mean maximum syrinx diameter and syrinx diameter reduction were 7.02 ± 2.94 mm and 3.41 ± 3.31 mm, respectively. The mean TD was 18.1 ± 6.92 mm preoperatively and the TD increased by 3.73 ± 2.88 mm at the 1-year follow-up. The mean C2–C7 sagittal Cobb angle, basal angles, clivo-axial angles, Wiesel-Rothman interval, basion-axial interval, and ADI were $19.9^\circ \pm 10.9^\circ$, $134.3^\circ \pm 7.4^\circ$, $145.1^\circ \pm 10.3^\circ$, 0.74 ± 0.51 mm, 7.65 ± 2.36 mm, and 2.04 ± 1.49 mm, respectively (Table 1).

2. Comparison of the syrinx reduction and nonreduction groups

At the 1-year follow-up, the syrinx diameter had decreased in 11 patients (57.8%, syrinx reduction group) and remained unchanged in eight patients (42.2%, syrinx nonreduction group). At the final follow-up, syrinx reduction was observed in 13 of 19 patients (68.4%) showing upward cerebellar tonsil shifting. The mean age was 23.8 ± 14.7 years (range, 6–53 years) and 31.8 ± 24.2 years (range, 3–66 years) in the reduction and nonreduction groups, respectively ($p=0.465$). The follow-up period was 57.6 ± 45.2 months (range, 12–132 months) and 61.5 ± 31.1 months (range, 12–120 months) in the reduction group and nonreduction groups, respectively ($p=0.457$). The mean preoperative syrinx length was 10.6 ± 5.3 and 14.1 ± 2.4 in the reduction and nonreduction groups, respectively ($p=0.135$). The preoperative coronal Cobb angle was $23.7^\circ \pm 17.2^\circ$ and $21.1^\circ \pm 10.6^\circ$ in the reduction and nonreduction groups, respectively ($p=0.865$). No difference was observed in the CCOS scores between the two groups in pain symptoms (2.94 ± 0.55 versus 2.75 ± 0.71 , $p=0.431$), nonpain symptoms (3.41 ± 0.71 versus 2.62 ± 1.06 , $p=0.061$), and complications (3.88 ± 0.33 versus 3.87 ± 0.35 , $p=0.958$). Significant differences were found in the functionality subscore (3.88 ± 0.33 vs. 2.75 ± 0.71 , $p<0.001$) and the total CCOS score (14.17 ± 1.24 versus 12.00 ± 1.77 , $p=0.005$). The preoperative maximum syrinx diameter was 7.08 ± 3.74 mm and 6.98 ± 1.84 mm in the reduction and nonreduction groups, respectively ($p=0.961$). The syrinx diameter reduction was 5.27 ± 2.61 mm and

Table 1. Overall outcomes of patients who underwent foramen magnum decompression for Chiari malformation type I

Characteristic	Value
Sex	
Male	9
Female	16
Age (yr)	26.4 ± 18.1
Follow-up (mo)	59.0 ± 40.0
Presence of syrinx	19 (76.0)
Length of syrinx	12.1 ± 4.5
Patients with scoliosis	17 (68.0)
Preoperative Cobb angle ($^\circ$)	22.7 ± 14.8
Complications	
Wound infection	None
Cerebrospinal fluid leak	1 (4.0)
Neurological complications	None
Vascular complications	None
Chicago Chiari Outcome Scale	
Pain	2.88 ± 0.61
Nonpain	3.16 ± 0.89
Functionality	3.52 ± 0.71
Complications	3.88 ± 0.33
Total score	13.48 ± 1.73
Clinical improvement	17/25 (68.0)
Syrinx improvement (within a year)	11 (57.8)
Maximum syrinx diameter (mm)	7.02 ± 2.94
Reduction syrinx diameter (mm)	3.41 ± 3.31
TD (mm)	18.1 ± 6.92
Increase TD (mm)	3.73 ± 2.88
Cervical alignment from C2 to C7 ($^\circ$)	19.9 ± 10.9
Basal angles ($^\circ$)	134.3 ± 7.4
Clivo-axial angles ($^\circ$)	145.1 ± 10.3
Wiesel-Rothman (mm)	0.74 ± 0.51
Basion-axial interval (mm)	7.65 ± 2.36
Atlanto-dens interval (mm)	2.04 ± 1.49

Values are presented as number, mean \pm standard deviation, or number (%). TD, tonsillar distance.

1.23 ± 0.67 mm in the reduction and nonreduction groups, respectively ($p=0.007$). The mean preoperative TD was 18.74 ± 7.15 mm and 17.21 ± 6.91 mm in the reduction and nonreduction groups, respectively ($p=0.798$). The groups showed a significant difference in increased TD (5.63 ± 2.37 mm versus 1.66 ± 1.69 , $p=0.0001$) but no significant differ-

Table 2. Comparison of the syrinx reduction and nonreduction groups

Characteristic	Syrinx reduction group (n=11)	Syrinx nonreduction group (n=8)	p-value	Power
Age (yr)	23.8±14.7	31.8±24.2	0.465	0.124
Follow-up (mo)	57.6±45.2	61.5±31.1	0.457	0.054
Length of syrinx	10.6±5.3	14.1±2.4	0.135	0.392
Preoperative Cobb angle (°)	23.7±17.2	21.1±10.6	0.865	0.065
Chicago Chiari Outcome Scale				
Pain	2.94±0.55	2.75±0.71	0.431	0.149
Nonpain	3.41±0.71	2.62±1.06	0.061	0.553
Functionality	3.88±0.33	2.75±0.71	<0.001*	0.993
Complications	3.88±0.33	3.87±0.35	0.958	0.056
Total score	14.17±1.24	12.00±1.77	0.005*	0.801
Maximum syrinx diameter (mm)	7.08±3.74	6.98±1.84	0.961	0.056
Reduction syrinx diameter (mm)	5.27±2.61	1.23±0.67	0.007*	0.986
TD (mm)	18.74±7.15	17.21±6.91	0.798	0.071
Increase TD (mm)	5.63±2.37	1.66±1.69	<0.001*	0.967
Cervical alignment from C2 to C7 (°)	18.5±11.5	22.8±9.7	0.357	0.125
Basal angles (°)	132.5±7.6	138.1±5.9	0.092	0.378
Clivo-axial angles (°)	145.7±11.4	143.7±8.3	0.691	0.068
Wiesel-Rothman interval (mm)	0.69±0.53	0.86±0.44	0.424	0.106
Basion-axial interval (mm)	8.18±2.09	6.61±2.65	0.086	0.255
Atlanto-dens interval (mm)	2.11±1.62	1.87±1.12	0.975	0.063

Values are presented as mean±standard deviation.

TD, tonsillar distance.

* $p < 0.05$ (statistically significant).

ences in the C2–C7 sagittal Cobb angle ($18.5^\circ \pm 11.5^\circ$ versus $22.8^\circ \pm 9.7^\circ$, $p=0.357$), basal angle ($132.5^\circ \pm 7.6^\circ$ versus $138.1^\circ \pm 5.9^\circ$, $p=0.092$), clivo-axial angle ($145.7^\circ \pm 11.4^\circ$ versus $143.7^\circ \pm 8.3^\circ$, $p=0.691$), Wiesel-Rothman interval (0.69 ± 0.53 mm versus 0.86 ± 0.44 mm, $p=0.424$), basion-axial interval (8.18 ± 2.09 mm versus 6.61 ± 2.65 mm, $p=0.086$), and ADI (2.11 ± 1.62 mm versus 1.87 ± 1.12 mm, $p=0.975$) in preoperative radiographs (Table 2).

3. Comparison of clinically improved and unimproved groups

At the 1-year follow-up, 12 patients (63.1%) showed clinical improvement and 7 (36.9%) showed no clinical improvement with syringomyelia. The mean age was 20.9 ± 13.2 years (range, 4–53 years) and 37.6 ± 20.6 years (range, 3–66 years) in the improved and unimproved groups, respectively, and the patients were significantly younger in the improved group ($p=0.028$). The follow-up

period was 52.3 ± 40.1 months (range, 12–132 months) and 55.2 ± 37.6 months (range, 12–84 months) in the improved and unimproved groups, respectively ($p=0.736$). The mean preoperative syrinx length was 11.1 ± 5.4 and 13.7 ± 2.2 in the improved and unimproved groups, respectively ($p=0.307$). The preoperative Cobb angle was $23.6^\circ \pm 17.2^\circ$ and $21.1^\circ \pm 10.6^\circ$ in the improved and unimproved groups, respectively ($p=0.865$). No difference was observed in the CCOS scores between the two groups in pain symptoms (2.92 ± 0.61 versus 2.57 ± 0.53 , $p=0.208$) and complications (3.92 ± 0.26 versus 3.71 ± 0.49 , $p=0.196$). Significant differences were found in nonpain symptoms (3.64 ± 0.49 versus 2.28 ± 0.95 , $p=0.002$), functionality subscore (3.92 ± 0.26 versus 2.71 ± 0.48 , $p < 0.001$), and total CCOS score (14.47 ± 1.01 versus 11.37 ± 0.74 , $p < 0.001$). The preoperative maximum syrinx diameter was 7.05 ± 3.26 mm and 6.82 ± 1.93 mm in the improved and unimproved groups, respectively ($p=0.898$). The syrinx diameter reduction was longer in the improved than the unimproved group

Table 3: Comparison of the clinical improved and unimproved groups

Characteristic	Clinically improved group (n=12)	Clinically unimproved group (n=7)	p-value	Power
Age (yr)	20.9±13.2	37.6±20.6	0.028*	0.462
Follow-up (mo)	52.3±40.1	55.2±37.6	0.736	0.052
Length of syrinx	11.1±5.4	13.7±2.2	0.307	0.231
Preoperative Cobb angle (°)	23.6±17.2	21.1±10.6	0.865	0.063
Chicago Chiari Outcome Scale				
Pain	2.92±0.61	2.57±0.53	0.208	0.344
Nonpain	3.64±0.49	2.28±0.95	0.002*	0.977
Functionality	3.92±0.26	2.71±0.48	<0.001*	0.999
Complications	3.92±0.26	3.71±0.49	0.196	0.288
Total score	14.47±1.01	11.37±0.74	<0.001*	0.999
Maximum syrinx diameter (mm)	7.05±3.26	6.82±1.93	0.898	0.053
Reduction syrinx diameter (mm)	4.42±4.04	0.56±0.49	0.004*	0.735
TD (mm)	18.12±7.25	17.38±7.44	0.971	0.054
Increase TD (mm)	5.32±2.52	1.11±0.64	<0.001*	0.992
Cervical alignment from C2 to C7 (°)	17.3±10.9	25.2±9.4	0.103	0.323
Basal angles (°)	133.5±7.4	136.2±7.7	0.477	0.106
Clivo-axial angles (°)	145.2±11.2	143.6±11.1	0.854	0.058
Wiesel-Rothman (mm)	0.74±0.59	0.74±0.32	0.853	0.052
Basion-axial interval (mm)	7.05±8.38	7.02±2.60	0.192	0.054
Atlanto-dens interval (mm)	2.13±1.67	1.85±1.11	0.829	0.066

Values are presented as mean±standard deviation.

TD, tonsillar distance.

* $p < 0.05$ (statistically significant).

(4.42±4.04 mm versus 0.56±0.49, $p=0.004$). The mean preoperative TD was 18.12±7.25 mm and 17.38±7.44 mm in the improved and unimproved groups, respectively ($p=0.971$). The two groups showed significant differences in increased TD (5.32±2.52 mm versus 1.11±0.64 mm, $p=0.0002$). No significant intergroup differences were found in the C2–C7 sagittal Cobb angle (17.3°±10.9° versus 25.2°±9.4°, $p=0.103$), basal angle (133.5°±7.4° versus 136.2°±7.7°, $p=0.477$), clivo-axial angle (145.2°±11.1° versus 143.6°±11.1°, $p=0.854$), Wiesel-Rothman interval (0.74±0.59 mm versus 0.74±0.32 mm, $p=0.853$), basion-axial interval (7.05±8.38 mm versus 7.02±2.60 mm, $p=0.192$), and ADI (2.13±1.67 mm versus 1.85±1.11 mm, $p=0.829$) in preoperative radiographs (Table 3).

Discussion

We investigated the potential factors associated with syrinx reduction in CMI and revealed a significant upward

bulbopontine sulcus shifting after surgery in the syrinx reduction group and the clinically improved group. Additionally, we obtained favorable clinical outcomes for younger age and upward bulbopontine sulcus shifting.

FMD is widely accepted as the treatment for the syringomyelia-CMI complex. According to a recent systematic review and meta-analysis, the syrinx radiological improvement rate after FMD without a dura opening was inferior to that with a dura opening [21]. However, previous reports demonstrated that FMD without a dura opening was associated with a lower risk of complications than that with a dura opening [8,22]. We performed FMD with outer dural mater layer excision as the first choice of surgical treatment in CMI, and 68.0% of the patients showed an improvement in clinical symptoms, 57.8% showed syrinx reduction, and only one patient showed a CSF leakage. No revision surgery was performed in this study because none of the patients had serious complications or symptom deterioration postoperatively. When the symptoms

get worse with a syrinx enlargement, we should consider revision surgery with duraplasty or shunt surgery. Thus, FMD with outer dural layer excision may provide optimal benefit with a low risk of postoperative complications.

Several factors, such as sex, age, length of follow-up, preoperative syrinx size, and cerebellar tonsil descent, have been reported as predictors of better surgical outcomes after FMD [9,10,12,16]. Badie et al. [16] reported that female patients showed a better response to FMD than male patients. Park et al. [9] reported that the longer the syringomyelia, the greater the syrinx improvement. Wu et al. [10] reported that patients with a more severe cerebellar tonsil descent would acquire more benefits from FMD. Our study revealed no significant differences regarding these parameters. This result may indicate that these parameters do not have a strong influence on syrinx reduction.

A few studies have attempted to evaluate preoperative craniocervical morphometric factors to predict syrinx resolution after FMD. Alperin et al. [23] suggested that physiological measures can be stronger predictors than morphological measures of posterior cranial fossa after FMD for CMI. Liu et al. [24] concluded that the morphology of the posterior cranial fossa cannot predict the response to FMD in patients with CMI. Our study revealed no significant changes in the bone morphometric parameters of the craniocervical junction, as well as the atlanto-occipital instability, such as the Wiesel-Rothman interval, basion-axial interval, and ADI. These results showed that preoperative morphological parameters did not affect syrinx reduction, as described in previous studies.

Few studies have investigated changes in the morphology of the hindbrain following FMD for CMI. Heiss et al. [25] drew a line between the basion and opisthion and selected it as the baseline and reported that pointed tonsils became round and CSF pathways significantly expanded both ventrally and dorsally at the craniocervical junction in adult patients with CMI after FMD. Xie et al. [26] selected a line crossing the clivus vertex and parallel with the C2 vertebral endplate as the baseline to evaluate the hindbrain position and showed significantly upward bulbopontine sulcus shifting. Our study selected the C2 vertebral endplate as a baseline because it was easy to measure and unchanged after FMD. As previous studies have shown, significant upward bulbopontine sulcus shifting was observed, implying that the deformed cerebellum could revert to its normal morphology with cerebellar tonsil ascent and the presence of the round tonsil. Poste-

rior fossa decompression and upward shifting of the tip of the cerebellar tonsil may normalize the CSF flow at the foramen magnum level and facilitate syrinx resolution.

The present study had several limitations. Firstly, it is a retrospective study, which may have introduced a memory bias in the data collection. Secondly, the sample size was relatively small, which limited the study's statistical power. Thus, future prospective large-sample studies are necessary to overcome these limitations.

Conclusions

Postoperative syrinx reduction was significantly correlated with the upward shifting of the tip of the cerebellar tonsil in patients with CMI. Our quantitative evaluation of hindbrain position alterations after FMD was easily performed and reflects the clinical outcomes.

Conflict of Interest

No potential conflict of interest relevant to this article was reported.

Author Contributions

Toshiaki Maruyama wrote and prepared the manuscript, Toshio Nakamae designed this study, and all authors have read, reviewed, and approved the article.

Supplementary Materials

Supplementary materials can be available from <https://doi.org/10.5999/aps.2022.0017>. Supplement 1. Intraoperative video demonstrating surgical procedure.

References

1. Rhoton AL Jr. Microsurgery of Arnold-Chiari malformation in adults with and without hydromyelia. *J Neurosurg* 1976;45:473-83.
2. Heiss JD, Snyder K, Peterson MM, et al. Pathophysiology of primary spinal syringomyelia. *J Neurosurg Spine* 2012;17:367-80.
3. Elster AD, Chen MY. Chiari I malformations: clinical and radiologic reappraisal. *Radiology* 1992;183:347-53.
4. Oldfield EH, Muraszko K, Shawker TH, Patronas NJ. Pathophysiology of syringomyelia associated with Chi-

- ari I malformation of the cerebellar tonsils: implications for diagnosis and treatment. *J Neurosurg* 1994;80:3-15.
5. Isu T, Sasaki H, Takamura H, Kobayashi N. Foramen magnum decompression with removal of the outer layer of the dura as treatment for syringomyelia occurring with Chiari I malformation. *Neurosurgery* 1993;33:845-9.
 6. Schijman E, Steinbok P. International survey on the management of Chiari I malformation and syringomyelia. *Childs Nerv Syst* 2004;20:341-8.
 7. Noudel R, Gomis P, Sotoares G, et al. Posterior fossa volume increase after surgery for Chiari malformation type I: a quantitative assessment using magnetic resonance imaging and correlations with the treatment response. *J Neurosurg* 2011;115:647-58.
 8. Durham SR, Fjeld-Olenec K. Comparison of posterior fossa decompression with and without duraplasty for the surgical treatment of Chiari malformation type I in pediatric patients: a meta-analysis. *J Neurosurg Pediatr* 2008;2:42-9.
 9. Park YS, Kim DS, Shim KW, Kim JH, Choi JU. Factors contributing to improvement of syringomyelia and surgical outcome in type I Chiari malformation. *Childs Nerv Syst* 2009;25:453-9.
 10. Wu T, Zhu Z, Jiang J, et al. Syrinx resolution after posterior fossa decompression in patients with scoliosis secondary to Chiari malformation type I. *Eur Spine J* 2012;21:1143-50.
 11. Lee HS, Lee SH, Kim ES, et al. Surgical results of arachnoid-preserving posterior fossa decompression for Chiari I malformation with associated syringomyelia. *J Clin Neurosci* 2012;19:557-60.
 12. Navarro R, Olavarria G, Seshadri R, Gonzales-Portillo G, McLone DG, Tomita T. Surgical results of posterior fossa decompression for patients with Chiari I malformation. *Childs Nerv Syst* 2004;20:349-56.
 13. Heiss JD, Suffredini G, Smith R, et al. Pathophysiology of persistent syringomyelia after decompressive craniocervical surgery: clinical article. *J Neurosurg Spine* 2010;13:729-42.
 14. Schuster JM, Zhang F, Norvell DC, Hermsmeyer JT. Persistent/recurrent syringomyelia after Chiari decompression-natural history and management strategies: a systematic review. *Evid Based Spine Care J* 2013;4:116-25.
 15. Gil Z, Rao S, Constantini S. Expansion of Chiari I-associated syringomyelia after posterior-fossa decompression. *Childs Nerv Syst* 2000;16:555-8.
 16. Badie B, Mendoza D, Batzdorf U. Posterior fossa volume and response to suboccipital decompression in patients with Chiari I malformation. *Neurosurgery* 1995;37:214-8.
 17. Smith BW, Strahle J, Bapuraj JR, Muraszko KM, Garton HJ, Maher CO. Distribution of cerebellar tonsil position: implications for understanding Chiari malformation. *J Neurosurg* 2013;119:812-9.
 18. Qiu Y, Zhu Z, Wang B, Yu Y, Qian B, Zhu F. Radiological presentations in relation to curve severity in scoliosis associated with syringomyelia. *J Pediatr Orthop* 2008;28:128-33.
 19. Aliaga L, Hekman KE, Yassari R, et al. A novel scoring system for assessing Chiari malformation type I treatment outcomes. *Neurosurgery* 2012;70:656-64.
 20. He Y, Zheng T, Wu B, Wang J. Significance of modified clivoaxial angles in the treatment of adult Chiari malformation type I. *World Neurosurg* 2019;130:e1004-14.
 21. Perrini P, Anania Y, Cagnazzo F, Benedetto N, Morganti R, Di Carlo DT. Radiological outcome after surgical treatment of syringomyelia-Chiari I complex in adults: a systematic review and meta-analysis. *Neurosurg Rev* 2021;44:177-87.
 22. Sakushima K, Hida K, Yabe I, Tsuboi S, Uehara R, Sasaki H. Different surgical treatment techniques used by neurosurgeons and orthopedists for syringomyelia caused by Chiari I malformation in Japan. *J Neurosurg Spine* 2013;18:588-92.
 23. Alperin N, Loftus JR, Oliu CJ, et al. Magnetic resonance imaging measures of posterior cranial fossa morphology and cerebrospinal fluid physiology in Chiari malformation type I. *Neurosurgery* 2014;75:515-22.
 24. Liu Z, Hao Z, Hu S, Zhao Y, Li M. Predictive value of posterior cranial fossa morphology in the decompression of Chiari malformation type I: a retrospective observational study. *Medicine (Baltimore)* 2019;98:e15533.
 25. Heiss JD, Suffredini G, Bakhtian KD, Sarntinoranont M, Oldfield EH. Normalization of hindbrain morphology after decompression of Chiari malformation type I. *J Neurosurg* 2012;117:942-6.
 26. Xie D, Qiu Y, Sha S, et al. Syrinx resolution is correlated with the upward shifting of cerebellar tonsil following posterior fossa decompression in pediatric patients with Chiari malformation type I. *Eur Spine J* 2015;24:155-61.