



Cervical Spinous Process and Its Attached Muscles Maintain Lower Disk Lordosis: A Retrospective Study of 155 Patients Who Underwent Muscle-Preserving Double Laminectomies

Ryoma Aoyama¹, Junichi Yamane², Ken Ninomiya³, Yuichiro Takahashi¹,
Kazuya Kitamura⁴, Satoshi Nori⁵, Satoshi Suzuki⁵, Tateru Shiraishi¹

¹Department of Orthopedics, Tokyo Dental College Ichikawa General Hospital, Ichikawa, Japan

²Department of Orthopedics, Murayama Medical Center, Musashimurayama, Japan

³Department of Orthopedics, Shizuoka City Shimizu Hospital, Shizuoka, Japan

⁴Department of Orthopedics, National Defense Medical College, Tokorozawa, Japan

⁵Department of Orthopedics, Keio University, Shinjuku, Japan

Study Design: A retrospective study conducted at a single academic institution.

Purpose: This study compared the postoperative alignment of consecutive double laminectomies according to their decompression levels and investigated the influence of the extension unit of the spinous process and its attached muscles on postoperative alignment.

Overview of Literature: Many reports have investigated bony and soft tissue factors as the causes of postoperative cervical alignment disorders. To-this-date, no other article has clarified the importance of the attached muscles between the spinous processes of C3 and C6 to maintain local cervical alignment.

Methods: In total, 155 consecutive patients who underwent muscle-preserving consecutive double laminectomies for cervical spondylotic myelopathy from 2005 to 2013 were included in this study. The imaging parameters included the C2–C7 angle, range of motion, C2–C7 sagittal vertical axis (SVA), C7 slope, C2–C5 angle, C5–C7 angle, local disk angle caudal to the decompression level, and the disk height between C2/C3 and C7/Th1.

Results: The caudal disk angle of the decompression level decreased after consecutive double laminectomies, thus suggesting that the extension unit maintained the local lordosis at the lower disk of the decompression level. Postoperatively, in the C3–4 decompression cases, the C2–C7 angle decreased by 7.3°, and the C2–C7 SVA increased by 8.6 mm, thus indicating the appearance of an alignment disorder. Multivariate logistic regression analysis showed that cephalad laminectomy was a risk factor for C2–C7 angle decreases >10°. However, the postoperative recovery rate of Japanese Orthopedic Association scores after consecutive double laminectomies was reasonable, and the overall cervical alignment was well maintained in all decompression levels except C3–C4.

Conclusions: The cervical extension unit maintained lordosis at the disk caudal to it. The extension unit was found to contribute more to the maintenance of lordosis of the entire cervical spine at the cephalad side.

Keywords: Alignment; Laminectomy; Laminoplasty; Muscle-preserving; Double laminectomy

Received May 12, 2021; Revised Aug 25, 2021; Accepted Sep 1, 2021

Corresponding author: Ryoma Aoyama

Department of Orthopedic Surgery, Tokyo Dental College Ichikawa General Hospital, 5-11-13 Sugano Ichikawa city, Chiba 272-8513, Japan

Tel: +81-47-322-0151, Fax: +81-47-325-4456, E-mail: aoyamar@tdc.ac.jp

Introduction

Postoperative alignment problems, including kyphotic deformity in the cervical spine, are factors that worsen the postoperative prognosis and reduce the patient's satisfaction in relation to the surgical procedure [1,2].

Many reports have investigated bony and soft tissue factors as the causes of this postoperative alignment disorder [3,4]. In particular, the resection of the lamina alone in bony elements does not impair cervical spine stability, and resection of the facet joint causes cervical spine instability [3,5]. Regarding the soft tissue component, studies have focused on muscle and joint capsules [4,6], with many reports suggesting that damage to the muscles attached to C2 causes alignment disorders [7,8]. Additionally, other studies suggested that damage to the muscles attached to C7 causes the appearance of disorders [9]. Furthermore, it has been reported that damage to the articular capsule alone can cause cervical instability [6]. Muscle-preserving selective laminectomy is a technique that allows decompression without damaging the facet joint, the joint capsule, or muscles attached to C2 [10]. Therefore, we have reported that cervical spine alignment is well preserved after this technique [11-13].

However, in this technique, the spinous process is dissected at its base; this damages the insertion of the cervical semispinalis and multifidus muscles that attach to the spinous process [10]. We call the extension mechanism of the cervical spine—which consists of the spinous process and the muscles attached to it—as the extension unit. In a muscle-preserving selective laminectomy, one extension unit is damaged in single laminectomies, and two extension units are damaged in consecutive double laminectomies [12]. To-date, no other study has clarified the extent to which damage to this extension unit affects the maintenance of local alignment of the cervical spine. Accordingly, alignment analyses after muscle-preserving selective laminectomy without damage to the facet joint or articular capsule is suitable for clarifying the effects of damage to this extension unit alone.

Additionally, while prior studies stated that the attached muscles to the C2 and C7 spinous processes are important for maintaining postoperative cervical alignment [7,9], no other studies have clarified the importance of the attached muscles between the C3 and C6 spinous processes for maintaining cervical alignment. Furthermore, no other publication has described the differences at the level of

this group of muscles. In a muscle-preserving selective laminectomy, procedures are usually performed within the range of C3 to C6 to select the decompression level. The technique is suitable for the investigation of the influences of muscles on postoperative cervical alignment within this range [12].

This study compared the postoperative alignment of muscle-preserving, selective double laminectomy with the maximum possible preservation of posterior stabilizing tissues as a function of the decompression level. We investigated the influence of the extension unit of the spinous process and its attached muscles on postoperative alignment.

Materials and Methods

1. Design

We conducted this retrospective study at a single academic institution.

2. Ethical approval

This study was conducted in compliance with the principles of the Declaration of Helsinki. The study's protocol was reviewed and approved by the Institutional Review Board at the Tokyo Dental College Ichikawa General Hospital (IRB approval no., 254). Written informed consents were obtained from all patients.

3. Participants

In total, 155 consecutive patients with cervical spondylotic myelopathy who underwent muscle-preserving selective laminectomies of two adjacent laminae at our academic institution from 2005 to 2013 were selected and studied [10]. Our inclusion criteria for selective laminectomy were: symptomatic disease (at least one clinical sign of myelopathy) and evidence of spinal canal stenosis on cervical magnetic resonance imaging (MRI), or myelogram-computed tomography (CT). The exclusion criteria for this study were: (1) patients with diseases other than cervical spondylotic myelopathy; (2) cervical myelopathy cases with local kyphosis $>20^\circ$ and vertebral body slippage >3.5 mm were excluded because they did not undergo selective laminectomy [13]; and (3) cervical myelopathy cases with laminectomy of one lamina and cases with a

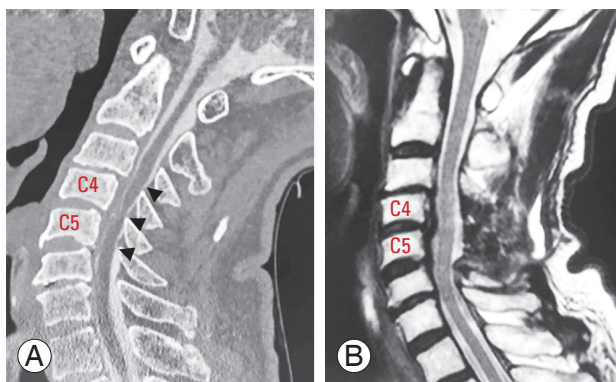


Fig. 1. (A, B) Preoperative myelogram-computed tomography (CT) in extended position and postoperative magnetic resonance imaging (MRI) in a neutral position of a case with two consecutive laminectomies. The left CT sagittal section shows three intervertebral stenoses (arrowhead) between C3/4 and C5/6. The postoperative MRI on the right shows the decompression of the three intervertebral spaces by C4–5 laminectomy.

laminectomy of three or more laminae. To determine the decompression level, the intervertebral disc level with the disappearance of the subarachnoid space in the cervical extended position was used as the decompression level. Myelography was performed in almost all patients who underwent surgery, and the disappearance of the subarachnoid space was determined by myelogram-CT of the extended cervical position performed preoperatively. However, for patients who could not undergo myelography owing to allergies, preoperative MRI was performed in the neutral and extended positions on the same day, and the intervertebral disc level where the subarachnoid space disappeared on MRI in the extended position was used as the decompression level (Fig. 1).

4. Surgical techniques of muscle-preserving selective laminectomy

Muscle-preserving selective laminectomy was performed using an operating microscope [10-13]. Using selective laminectomy of two adjacent laminae, three adjacent intervertebral levels were decompressed. The surgical technique used for double laminectomy at C5–C6 was as follows. After the interlaminar spaces between C4 and C5, C5, and C6, and C6 and C7 were exposed using our technique, and the C5 and C6 spinous processes were split longitudinally using a high-speed drill. The spinous processes were then divided at its base, leaving the bilateral deep extensor muscles undisturbed. The C5 and C6 laminae, the upper half of the C7 lamina, and the yellow

ligament of the ventral aspect of the C4 lamina were then removed. Thus, adjacent tree-level (C4/C5, C5/C6, and C6/C7) decompression was completed.

5. Clinical outcomes

The clinical outcomes were evaluated using the Japanese Orthopedic Association (JOA) score preoperatively and at the final follow-up. The recovery rate of the JOA score was calculated using the method of Hirabayashi et al. [14].

6. Analysis of radiological findings

Two spinal surgeons independently performed the radiological evaluations using a digital imaging and communications in medicine viewer (Synapse ver. 4.1.0; FUJIFILM Medical, Tokyo, Japan). For postoperative image evaluation, images at the final follow-up were used. Standing lateral view plain radiographs were obtained with the neck in a neutral posture, flexion, and extension, preoperatively, and at the final follow-up. Neutral posture lateral radiographs were obtained with the patient standing in a comfortable position with the head facing forward and gazing in the horizontal direction. The C2–C7 angle was measured as the Cobb angle between the C2 and C7 vertebral bodies. A positive value in the C2–C7 angle indicates lordosis in this study. The range of motion (ROM) was calculated as the difference between the C2–C7 angle during flexion and extension. We defined the C2–C7 sagittal vertical axis (SVA) as the distance between the C2 plumb line and the superior posterior corner of the C7 vertebral body. The C7 slope was determined as the angle between the superior endplate of C7 and a horizontal line. The angles associated with C2–C5 and C5–C7 angle were measured in the same way as the angle for C2–C7 [13].

The lower disk angle (LDA) was defined as the disk angle at the decompression site. LDA was measured as the C4–C5 Cobb angle for C3–C4 laminectomies, C5–C6 Cobb angle for C4–C5 laminectomies, C6–C7 angle for C5–C6 laminectomies, and C7–Th1 angle for C6–C7 laminectomies (Fig. 2). A positive LDA value means lordosis at the targeted disk in this study.

We evaluated the intervertebral disc height according to the Matsumoto method [15,16]. We defined disk height grade (DHG) as the percentage of height reduction compared with the most adjacent normal disk on sagittal magnetic resonance images, graded from 0 to 2: grade 0,

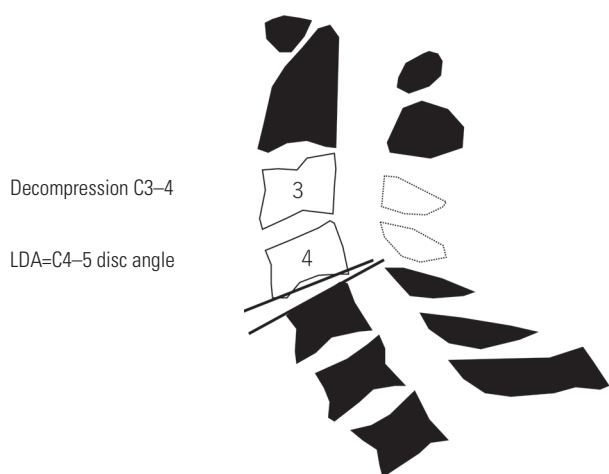

Fig. 2. Lower disc angle. Lower disc angle (LDA) was defined as a LDA at the decompression site. LDA was measured as C4–C5 Cobb angle for C3–4 laminectomy.

no narrowing of the disk space, grade 1, less than 50% loss of height, and grade 2 more than 50% loss of height. The total disk height is the sum of the grades of all intervertebral discs. The lower adjacent DHG was the DHG of the intervertebral space measured at the LDA.

7. Statistical analysis

Statistical analysis was performed using the software IBM SPSS ver. 25.0 (IBM Corp., Armonk, NY, USA). All values were expressed as the means±standard deviations and were considered significant when $p < 0.05$. Comparison of each independent variable among the four groups was performed using one-way analysis of variance for continuous variables, and the Kruskal-Wallis test for discrete variables. Logistic regression analysis was used for risk factor analysis. First, a univariate analysis was used to determine the significance of various parameters. Factors with $p < 0.20$ in the univariate analysis were then included in the multivariate analysis. Comparisons of all independent variables between the two groups were performed using the *t*-test for continuous variables and the Mann-Whitney *U* test for discrete variables.

Results

1. Demographics of patients and surgical outcomes

There were 110 men and 45 women in this study. The mean age was 63.9 years, and the follow-up period aver-

aged 2 years and 1 month. C3–C4 laminectomies were performed in nine patients (5.9%), C4–C5 laminectomies in 53 patients (34.2%), C5–C6 laminectomies in 82 patients (52.9%), and C6–C7 laminectomies in 11 patients (7.1%). The mean age of C3–C4 laminectomy patients was 75.6 years. There were no significant differences in the male/female ratio among the four groups classified based on the decompression levels. There were no significant differences in the operation time or intraoperative blood loss among the four groups. The preoperative JOA score was not significantly different between the four groups, but the postoperative JOA score was significantly higher in the C5–C6 laminectomy cases compared with the C4–C5 laminectomy cases. The improvement rate of the JOA score was 29.3% in the C4–C5 laminectomy cases, which was significantly lower than that in C5–C6 laminectomy cases (Table 1).

2. C2–C7 angle, ROM, C2–C7 SVA, C7 slope, C2–C5 angle, C5–C7 angle, and LDA

The preoperative C2–C7 angle was 13.8° in C4–C5 laminectomy cases. The postoperative C2–C7 angle was also significantly higher at 15.1° in the C4–C5 laminectomy cases. The change in the C2–C7 angle before and after surgery was negative only in the C3–C4 laminectomy cases, and the C2–C7 angle increased after surgery in the other three groups. There was no significant difference in the preoperative C2–C7 angle in flexion and in the C2–C7 angle in extension among the four groups. There was no significant difference in ROM among the four groups. Preoperative C2–C7 SVA was equal to 38.5 mm in C3–C4 laminectomy cases. Postoperative C2–C7 SVA in C3–C4 laminectomy cases was equal to 48.1 mm. The C2–C7 SVA increased after surgery by 8.6 mm in C3–4 laminectomy cases, which was a significantly higher increase. The preoperative C7 slope value was significantly higher in C3–C4 laminectomy cases, and the postoperative C7 slope was higher in C3–C4 laminectomy cases but the change was not significant. The changes in the C7 slope before and after surgery were not significantly different among the four groups. The preoperative C2–C5 angle was significantly higher in C4–C5 laminectomy cases at 8.2° , but the postoperative C2–C5 angle was not significantly different among the four groups. The changes in the C2–C5 angle before and after surgery were not significantly different among the four groups and increased in all cases with the

Table 1. Demographics of patients, surgical outcomes, and radiological findings among the four groups divided by the decompression level

Characteristic	SL3-4	SL4-5	SL5-6	SL6-7	p-value
No. of patients	9	53	82	11	
Age (yr)	75.6±10.6	67.1±10.2	60.5±10.9	64.8±10.8	<0.001
Sex					0.073
Male	7	44	53	6	
Female	2	9	29	5	
Operation time (min)	125.3±25.3	126.1±33.7	125.9±31.3	148.5±30.4	0.172
Blood loss (g)	14.3±37.8	4.5±22.6	19.4±51.6	36.0±36.6	0.102
Pre JOA score (full 17)	9.9±2.3	10.8±3.1	11.6±2.3	12.0±1.9	0.18
Post JOA score	12.6±1.8	12.7±2.7	14.1±1.9	14.4±1.4	0.002
RR of JOA score	39.1±16.8	29.3±23.5	42.9±27.2	45.2±25.8	0.029
Pre C2-C7 angle (°)	8.8±14.8	13.8±11.1	8.2±10.4	4.8±8.8	0.015
Post C2-C7 angle (°)	1.5±23.9	15.1±12.1	9.5±10.5	9.0±9.3	0.007
Post-Pre C2-C7 angle (°)	-7.3±17.2	1.3±7.0	1.3±6.2	3.8±9.3	0.013
Pre Flex C2-C7 angle (°)	-6.8±14.8	-9.5±11.1	-12.6±11.6	-17.9±9.2	0.194
Pre Ext C2-C7 angle (°)	21.8±20.0	28.1±13.7	24.1±10.2	16.6±10.3	0.073
Pre ROM	28.5±8.7	37.6±15.1	36.7±12.0	34.4±11.6	0.580
Pre C2-C7 SVA (mm)	38.5±19.7	22.3±13.5	23.0±10.8	21.9±9.4	0.008
Post C2-C7 SVA (mm)	48.1±20.3	22.9±12.4	22.2±11.4	23.1±12.4	<0.001
Post-Pre C2-C7 SVA (mm)	8.6±11.1	0.5±8.5	-0.7±6.9	1.3±10.6	0.016
Pre C7 slope (°)	36.8±7.5	25.8±11.1	21.2±8.8	18.9±10.2	0.001
Post C7 slope (°)	34.5±14.8	25.9±11.1	22.6±10.2	24.3±6.6	0.095
Post-Pre C7 slope (°)	-2.3±11.9	0.1±6.3	1.5±5.6	5.4±6.4	0.117
Pre C2-C5 angle (°)	6.9±9.6	8.2±8.7	3.8±8.8	-1.4±1.5	0.010
Post C2-C5 angle (°)	6.1±16.7	11.4±10.5	8.7±9.6	2.0±8.7	0.109
Post-Pre C2-C5 angle (°)	-0.8±16.7	3.2±5.6	4.9±7.1	3.4±8.0	0.194
Pre C5-C7 angle (°)	-1.3±5.0	7.1±6.3	4.4±5.2	3.7±4.4	<0.001
Post C5-C7 angle (°)	0.0±9.4	4.8±7.4	3.4±6.5	5.6±8.3	0.269
Post-Pre C5-C7 angle (°)	1.3±5.6	-2.3±4.9	-1.0±4.5	1.9±7.5	0.058
Pre lower disc angle (°)	-2.0±3.6	3.2±3.6	1.7±3.0	5.0±2.1	<0.001
Post lower disc angle (°)	-1.9±5.8	1.1±3.7	0.6±4.0	2.5±3.6	0.145
Post-Pre lower disc angle (°)	0.1±3.5	-2.3±2.7	-1.1±3.5	-2.1±3.0	0.133
DHG C2/3	0.3±0.5	0.8±0.6	0.8±0.5	0.6±0.6	0.066
DHG C3/4	1.1±0.6	1.1±0.7	0.8±0.7	0.8±0.7	0.14
DHG C4/5	0.7±0.9	1.3±0.6	1.1±0.7	0.6±0.9	0.016
DHG C5/6	0.8±0.7	1.6±0.5	1.6±0.5	1.1±0.6	0.001
DHG C6/7	1.2±0.7	1.2±0.7	1.4±0.6	1.4±0.5	0.561
DHG C7/Th1	0.9±0.6	0.8±0.6	0.8±0.6	0.5±0.5	0.443
Total DHG	5.0±2.4	6.8±2.3	6.5±2.1	5.0±3.1	0.072
Lower DHG	0.7±0.9	1.6±0.5	1.4±0.6	0.5±0.5	0.001

Values are presented as mean±standard deviation, unless otherwise stated. The bold type is considered statistically significant.

SL, selective laminectomy; JOA, Japanese Orthopedic Association; RR, recovery rate; Flex, flexion; Ext, extension; ROM, range of motion; SVA, sagittal vertical axis; DHG, disc height grade.

exception of the C3–C4 laminectomy cases. The preoperative C5–C7 angle was significantly lower in the C3–C4 laminectomy cases at -1.3° , but the postoperative C5–C7 angles were not significantly different among the four groups. C5–C7 angle changes before and after surgery were not significantly different among the four groups. The preoperative LDA was significantly lower in the C3–C4 laminectomy cases at -2.0° , but the postoperative LDA was not significantly different among the four groups. The changes in the LDA before and after surgery were negative in the three groups except the C3–C4 laminectomy cases. Furthermore, there was no significant difference among the four groups (Table 1).

3. DHG

In the preoperative DHG comparison of disk heights, significant differences were observed in the C4/C5 and C5/C6 cases. A significant decrease in disk height was observed in the C4/C5 disk heights in the C4–C5 laminectomy cases, and a significant residual disk height was observed in the C5/C6 disk heights in the C3–C4 laminectomy cases. The total DHG values, which represent the disk heights of the entire cervical spine, were not significantly different among the four groups. The lower DHG values were significantly higher in the cases of the C4–C5 and C5–C6 laminectomies, thus indicating a decrease in disk height caudal to the decompression site.

Table 2. Risk factor analysis for C2–C7 angle decrease $\geq 10^\circ$

Variable	Univariate		Multivariate	
	p-value	OR (95% CI)	p-value	OR (95% CI)
Decompression level	0.035	0.391 (0.163–0.938)	0.032	0.262 (0.077–0.892)
Age	0.976			
Male/female	0.974			
Operation time	0.856			
Blood loss	0.557			
Pre JOA score	0.94			
Pre C2–C7 angle	0.405			
Pre Flex C2–C7 angle	0.409			
Pre Ext C2–C7 angle	0.430			
Pre ROM	0.993			
Pre C2–C7 SVA	0.177		0.872	
Pre C7 slope	0.132		0.824	
Pre C2–C5 angle	0.907			
Pre C5–C7 angle	0.456			
Pre lower disc angle	0.102		0.509	
DHG C2/3	0.005	0.147 (0.038–0.567)	0.025	0.152 (0.029–0.794)
DHG C3/4	0.522			
DHG C4/5	0.550			
DHG C5/6	0.042	0.351 (0.128–0.965)	0.631	
DHG C6/7	0.526			
DHG C7/Th1	0.427			
Total DHG	0.101		0.716	
Lower DHG	0.391			

The decompression levels were analyzed as follows: C3–4 laminectomy, 3; C4–5 laminectomy, 4; C5–6 laminectomy, 5; and C6–7 laminectomy, 6. The bold type is considered statistically significant.

OR, odds ratio; CI, confidence interval; JOA, Japanese Orthopedic Association; Flex, flexion; Ext, extension; ROM, range of motion; SVA, sagittal vertical axis; DHG, disc height grade.

4. Risk factor analysis for C2–C7 angle decreases

The risk factors for C2–C7 angle decreases $\geq 10^\circ$ before and after surgery were analyzed (Tables 2, 3). Univariate logistic regression analyses were performed for the decompression level, age, sex ratio, operation time, intraoperative blood loss, JOA score, C2–C7 angle, flexion, and extension C2–C7 angle, ROM, C2–C7 SVA, C7 slope, C2–C5 angle, C5–C7 angle, LDA, DHG at each disk level, total DHG, and lower DHG. We analyzed only the preoperative values. The decompression levels were analyzed as follows: C3–C4 laminectomy, 3; C4–5 laminectomy, 4; C5–C6 laminectomy, 5; and C6–7 laminectomy, 6. Univariate logistic regression analysis showed that the decompression level and DHG at C2/C3 and C5/C6 were significant risk factors for a decrease in the C2–C7 angle post-surgery. Multivariate logistic regression analysis showed that the decompression level was a significant risk factor with an odds ratio of 0.262, and that the incidence was approximately 3.8 times higher when the decompression level was one level cephalad. Multivariate logistic regression analysis also showed that the disk height at C2/C3 was a significant risk factor with an odds ratio of 0.152, and that the incidence was approximately 6.6 times higher when the DHG at C2/C3 was one level lower. These findings mean that the preserved disk height at C2/C3 was a risk factor for C2–C7 angle decreases.

5. Risk factor analysis for C2–C7 SVA increases

The risk factor analysis for C2–C7 SVA increases ≥ 15 mm before and after surgery showed that age, ROM, and the C7 slope were significant risk factors in the univariate logistic regression analysis. In multivariate logistic regression analysis, ROM was a significant risk factor with an

odds ratio of 0.885, thus indicating that a 1° decrease in the ROM was associated with a 1.1-fold increase in incidence (Tables 4, 5).

6. Age-matched analysis for cervical alignment

Cervical spine alignment was examined in 59 age-matched cases to eliminate the age factor. There was no significant difference in the preoperative C2–C7 angle, but the postoperative C2–C7 angle was significantly lower in C3–C4 laminectomy cases. The change in the C2–C7 angle before and after surgery was significantly lower in C3–C4 laminectomy cases. There was no significant difference in preoperative C2–C7 SVA, but postoperative C2–C7 SVA was significantly higher in C3–C4 laminectomy cases. The change in C2–C7 SVA before and after surgery was higher in C3–C4 laminectomy cases but insignificant. There were no significant differences between the pre- and postoperative C7 slopes and in the slope changes in C7 among the four groups (Table 6).

Discussion

In this study, the lower local angle decreased after consecutive double laminectomies with the exception of the C3–C4 laminectomy cases. The C3–C4 laminectomy group exhibited lower local kyphosis before surgery, and the kyphosis did not progress postoperatively. This was probably owing to the preoperative kyphosis. The results of this study revealed that the local kyphosis at the disk caudal to the decompression level progressed after consecutive double laminectomies. This result supports the fact that the deep extensor muscles of the cervical spine maintained their alignments as a dynamic stabilizer muscle group [4,17]. To our knowledge, this study is also the first report to show that the deep extensor muscles of the cervical spine influenced the maintenance of local alignment of the cervical spine. Although the mechanism for this phenomenon is unclear, we hypothesized the mechanism. When the spinous process was split longitudinally and the local extension unit was damaged, muscle tone around the facet joint at the muscle origin was weakened and the stabilization mechanism around the joint was impaired. This resulted in abnormal local alignment. We reported that after muscle-preserving selective laminectomy, caudal lordosis of the cervical spine decreased, and the cephalad lordosis increased to compensate; these changes

Table 3. Number of cases and the mean values of factors that were significant risks in the univariate logistic regression analysis for C2–C7 angle decrease $\geq 10^\circ$

C2–C7 angle decrease	$\geq 10^\circ$	$< 10^\circ$	<i>p</i> -value
No. of patients	11	144	
Decompression level	4.2 \pm 0.9	4.7 \pm 0.7	0.030
DHG C2/3	0.3 \pm 0.5	0.8 \pm 0.6	0.002
DHG C5/6	1.2 \pm 0.4	1.6 \pm 0.6	0.034

Values are presented as mean \pm standard deviation, unless otherwise stated. DHG, disc height grade.

Table 4. Risk factor analysis for C2–C7 SVA increase ≥15 mm

Variable	Univariate		Multivariate	
	p-value	OR (95% CI)	p-value	OR (95% CI)
Decompression level	0.075		0.440	
Age	0.014	1.116 (1.023–1.218)	0.420	
Male/female	0.542			
Operation time (min)	0.429			
Blood loss (g)	0.503			
Pre JOA score	0.314			
Pre C2–C7 angle	0.252			
Pre Flex C2–C7 angle	0.090			
Pre Ext C2–C7 angle	0.238			
Pre ROM	0.014	0.885 (0.803–0.975)	0.035	0.885 (0.791–0.991)
Pre C2–C7 SVA	0.572			
Pre C7 slope	0.013	1.094 (1.019–1.176)	0.079	1.074 (0.992–1.163)
Pre C2–C5 angle	0.180		0.795	
Pre C5–C7 angle	0.649			
Pre lower disc angle	0.074		0.265	
DHG C2/3	0.606			
DHG C3/4	0.422			
DHG C4/5	0.242			
DHG C5/6	0.186		0.135	
DHG C6/7	0.689			
DHG C7/Th1	0.068		0.523	
Total DHG	0.349			
Lower DHG	0.864			

The decompression levels were analyzed as follows: C3–4 laminectomy, 3; C4–5 laminectomy, 4; C5–6 laminectomy, 5; and C6–7 laminectomy, 6. The bold type is considered statistically significant. OR, odds ratio; CI, confidence interval; JOA, Japanese Orthopedic Association; Flex, flexion; Ext, extension; ROM, range of motion; SVA, sagittal vertical axis; DHG, disc height grade.

Table 5. Number of cases and the mean values of factors that were significant risks in the univariate logistic regression analysis for C2–C7 SVA increase ≥15 mm

C2–C7 SVA increase	≥15 mm	<15 mm	p-value
No. of patients	8	147	
Age (yr)	73.9±9.4	63.5±10.7	0.008
Pre C7 slope	32.7±18.3	22.7±8.8	0.008
Pre ROM	24.3±7.2	37.4±13.1	0.010

Values are presented as mean±standard deviation, unless otherwise stated. SVA, sagittal vertical axis; ROM, range of motion.

maintained the alignment of the entire cervical spine [13]. In this study, we could show that the mechanism of the caudal reduction in cervical lordosis was caused by local

kyphosis at the decompressed caudal intervertebral space. However, in a relatively less invasive double laminectomy, this local kyphosis was compensated by an effect on the cephalad side, and the overall cervical alignment became more lordotic postoperatively. Additionally, the recovery rate after this procedure was reasonable, and the results of the surgery were satisfactory.

The C2–C7 angle decreased after the C3–C4 laminectomy, and the C2–C7 SVA was also increased after the C3–C4 laminectomy. Based on the findings from this study, it is suggested that the cervical alignment deteriorated after the C3–C4 laminectomy. In addition, multivariate logistic regression analysis showed that the decompression level was significantly associated with C2–C7 angle decreases

Table 6. Age-matching analysis for cervical alignment

Variable	SL3-4	SL4-5	SL5-6	SL6-7	p-value
No. of patients	9	28	18	4	
Age (yr)	75.6±10.6	75.1±6.2	74.6±3.9	74.8±7.1	0.987
Sex					0.209
Male	7	20	10	1	
Female	2	8	8	3	
Pre C2-C7 angle	8.8±14.8	13.0±12.0	11.0±6.3	6.5±11.0	0.614
Post C2-C7 angle	1.5±23.9	16.4±11.5	12.8±8.1	15.0±5.0	0.049
Post-Pre C2-C7 angle	-7.3±17.2	3.4±6.2	1.8±7.5	8.5±6.9	0.016
Pre C2-C7 SVA (mm)	38.5±19.7	24.2±16.8	25.0±13.8	14.5±2.1	0.120
Post C2-C7 SVA (mm)	48.1±20.3	24.6±15.0	24.7±14.2	9.0±8.5	0.001
Post-Pre C2-C7 SVA (mm)	8.6±11.1	0.4±10.0	-0.4±7.6	-5.5±6.4	0.080
Pre C7 slope	36.8±7.5	25.7±11.0	25.2±9.2	15.5±9.2	0.124
Post C7 slope	34.5±14.8	28.0±12.6	26.8±10.8	19.5±6.4	0.518
Post-Pre C7 slope	-2.3±11.9	2.3±7.3	1.6±5.1	4.0±2.8	0.644

Values are presented as mean±standard deviation, unless otherwise stated. The bold type is considered statistically significant. SL, selective laminectomy; SVA, sagittal vertical axis.

>10°. This result indicated that the deep extensor muscles on the cephalad side contributed more profoundly to the maintenance of the overall cervical alignment. The lever arm of cervical extension became larger in the cervical extension unit on the cephalad side. Thus, it can be inferred that the cervical deep extensor muscles attached to the spinous process on the cephalad side are more able to maintain cervical lordosis. In fact, many previous studies have described how damage to the most cephalad extension unit C2 worsens cervical alignment [7,8]. Given that C2 is the most cephalad region to which the cervical extension mechanism attaches, it is easy to infer that it is the most active level in the maintenance of cervical lordosis. Using cadavers, Takeuchi showed that when C3 laminoplasty was performed, the cervical semispinalis muscle attached to C2 interfered with the posterior spinous processes and spacers [18]. The same authors showed that the cervical semispinalis muscle attached to C2 can be preserved by performing a C3 laminectomy and demonstrated its usefulness [8]. The C3 laminectomy technique does not require separation of the muscle attached to C2. Accordingly, our technique also does not require separation of the muscle attached to C2 during C3-C4 laminectomy. Thus, it is unlikely that the alignment loss in this study after C3-C4 laminectomy appeared owing to damage to the C2 attached muscles caused by the C3-C4 laminectomy.

Multivariate logistic regression analysis showed that the

preserved disk height at C2/C3 was significantly associated with C2-C7 angle decreases >10°. To the best of our knowledge, there is no report on the relationship between disk height at C2/C3 and postoperative alignment changes in the cervical spine. Given that C2/3 is the most cephalad disk, it is the last disc that can undergo compensatory alignment changes for alignment changes in the caudal part of the spine. The remaining disc height at C2/C3 may contribute to the tendency for alignment changes, but this mechanism remains unclear and requires further investigation.

To-this-date, no other study has clarified the contributions of C3 to C6 extension units to maintain cervical lordosis, and the results of this study indicate that as the extension unit becomes more cephalad, the ability to maintain cervical lordosis is enhanced. In this study, cervical alignment was maintained in patients who underwent C6-C7 laminectomies, thus suggesting that the deep extensor muscles attached to C6 and C7 were not involved in maintaining cervical lordosis; this was probably because the lever arm was considered the shortest.

In this study, patients who underwent C3-C4 laminectomies, i.e., patients with cephalad stenoses, were mostly elderly. Previous studies have also confirmed that elderly patients were more likely to suffer from cephalic stenoses [19]. It can be assumed that age affects postoperative changes [20]. In fact, C2-C7 SVA was high preoperatively

in C3–C4 laminectomy cases, which may be related to postoperative changes in SVA. However, multivariate logistic regression analysis of the factors responsible for the decrease in the C2–C7 angle by more than 10° and the increase in C2–C7 SVA by more than 15 mm showed that age and preoperative C2–C7 SVA were not significant aggravating factors, thus suggesting that the difference in the decompression level was the primary factor for postoperative alignment changes. The study of age-matched cervical spine alignment also showed a significant decrease in the C2–C7 angle and an increase in the C2–C7 SVA postoperatively in C3–C4 laminectomy cases. Considering all these results, it is suggested that as the number of cephalad extension units increased, its importance in maintaining cervical lordosis increased.

The multivariate logistic regression analysis of the factors contributing to the increase in the C2–C7 SVA >15 mm showed that the preoperative ROM was a significant factor. Many previous studies have reported that preoperative alignment abnormalities affect the postoperative period [1,2]. However, there are no reports that show that preoperative ROM affects sagittal plane imbalance. We have reported that cervical alignment was maintained by compensatory lordosis on the cephalad side even when there was loss of alignment on the lower cervical spine after selective laminectomy [13]. Regarding SVA, when alignment loss appeared in the lower part of the cervical spine, it should be compensated on the cranial side, but if the ROM was small, the compensatory action may be hard to be worked. This study suggests that cervical spine mobility is necessary to maintain the sagittal plane balance and that the remaining cervical ROM is advantageous in compensating for abnormal alignment.

In this study, we used a less invasive technique with a narrow decompression level of two adjacent laminae, and showed that the extension unit alone affected the caudal local alignment. Therefore, as wider decompression with wider exposure is commonly used in conventional laminoplasty [21,22], it can be expected that the effect of capsule and joint damage other than the extension unit may work strongly in laminoplasty. Moreover, there are limitations in directly applying the results of this study to conventional laminoplasty. In addition, the ROM restriction that occurs after conventional laminoplasty may affect the maintenance of postoperative alignment [21,22], and this may be an issue for additional investigations.

The influence of selection bias cannot be ruled out

based on the findings of this retrospective study. Furthermore, the lack of entire spine imaging evaluations which do not consider spinopelvic parameters is a limitation of the study. The small number of cases limited the reliability of the results of multivariate logistic regression analysis, and the influences of the older age of C3–C4 laminectomy cases could not be eliminated. The absence of a control group for comparison precludes an accurate evaluation. It is important that our technique is compared in the future with fusion or other techniques of decompression to clarify the difference in the occurrence of alignment changes owing to differences in the surgical invasion. A prospective comparative study with a large number of patients is desirable to elucidate the mechanism of alignment changes following surgery.

Conclusions

After consecutive double laminectomies, kyphosis developed at the disc which was caudal to the decompression site. In the lower cervical spine, the extension unit of the spinous process and its attached muscles is more likely to exert its function when it is located cephalad.

Conflict of Interest

No potential conflict of interest relevant to this article was reported.

Author Contributions

All authors contributed to the study conception and design. Material preparation, data collection, and analysis were performed by all authors. The first draft of the manuscript was written by Ryoma Aoyama, and all authors commented on previous versions of the manuscript. All authors read and approved the final manuscript.

References

1. Sakai K, Yoshii T, Hirai T, Arai Y, Shinomiya K, Okawa A. Impact of the surgical treatment for degenerative cervical myelopathy on the preoperative cervical sagittal balance: a review of prospective comparative cohort between anterior decompression with fusion and laminoplasty. *Eur Spine J* 2017;26:104-12.
2. Suda K, Abumi K, Ito M, Shono Y, Kaneda K, Fujiya

- M. Local kyphosis reduces surgical outcomes of expansive open-door laminoplasty for cervical spondylotic myelopathy. *Spine (Phila Pa 1976)* 2003;28:1258-62.
3. Nowinski GP, Visarius H, Nolte LP, Herkowitz HN. A biomechanical comparison of cervical laminoplasty and cervical laminectomy with progressive facetectomy. *Spine (Phila Pa 1976)* 1993;18:1995-2004.
 4. Nolan JP Jr, Sherk HH. Biomechanical evaluation of the extensor musculature of the cervical spine. *Spine (Phila Pa 1976)* 1988;13:9-11.
 5. Zdeblick TA, Zou D, Warden KE, McCabe R, Kunz D, Vanderby R. Cervical stability after foraminotomy: a biomechanical in vitro analysis. *J Bone Joint Surg Am* 1992;74:22-7.
 6. Zdeblick TA, Abitbol JJ, Kunz DN, McCabe RP, Garfin S. Cervical stability after sequential capsule resection. *Spine (Phila Pa 1976)* 1993;18:2005-8.
 7. Takeshita K, Seichi A, Akune T, Kawamura N, Kawaguchi H, Nakamura K. Can laminoplasty maintain the cervical alignment even when the C2 lamina is contained? *Spine (Phila Pa 1976)* 2005;30:1294-8.
 8. Takeuchi K, Yokoyama T, Aburakawa S, et al. Axial symptoms after cervical laminoplasty with C3 laminectomy compared with conventional C3-C7 laminoplasty: a modified laminoplasty preserving the semispinalis cervicis inserted into axis. *Spine (Phila Pa 1976)* 2005;30:2544-9.
 9. Sakaura H, Hosono N, Mukai Y, Oshima K, Iwasaki M, Yoshikawa H. Preservation of the nuchal ligament plays an important role in preventing unfavorable radiologic changes after laminoplasty. *J Spinal Disord Tech* 2008;21:338-43.
 10. Shiraishi T. A new technique for exposure of the cervical spine laminae: technical note. *J Neurosurg* 2002;96(1 Suppl):122-6.
 11. Shiraishi T, Fukuda K, Yato Y, Nakamura M, Ikegami T. Results of skip laminectomy: minimum 2-year follow-up study compared with open-door laminoplasty. *Spine (Phila Pa 1976)* 2003;28:2667-72.
 12. Shiraishi T, Kato M, Yato Y, et al. New techniques for exposure of posterior cervical spine through intermuscular planes and their surgical application. *Spine (Phila Pa 1976)* 2012;37:E286-96.
 13. Nori S, Shiraishi T, Aoyama R, et al. Muscle-preserving selective laminectomy maintained the compensatory mechanism of cervical lordosis after surgery. *Spine (Phila Pa 1976)* 2018;43:542-9.
 14. Hirabayashi K, Miyakawa J, Satomi K, Maruyama T, Wakano K. Operative results and postoperative progression of ossification among patients with ossification of cervical posterior longitudinal ligament. *Spine (Phila Pa 1976)* 1981;6:354-64.
 15. Matsumoto M, Fujimura Y, Suzuki N, et al. MRI of cervical intervertebral discs in asymptomatic subjects. *J Bone Joint Surg Br* 1998;80:19-24.
 16. Aoyama R, Shiraishi T, Kato M, et al. Characteristic findings on imaging of cervical spondylolisthesis: analysis of computed tomography and X-ray photography in 101 spondylolisthesis patients. *Spine Surg Relat Res* 2018;2:30-6.
 17. Wang D, Ding Y, Wu B, et al. Cervical extensor muscles play the role on malalignment of cervical spine: a case control study with surface electromyography assessment. *Spine (Phila Pa 1976)* 2021;46:E73-9.
 18. Takeuchi K, Yokoyama T, Aburakawa S, Itabashi T, Toh S. Anatomic study of the semispinalis cervicis for reattachment during laminoplasty. *Clin Orthop Relat Res* 2005;(436):126-31.
 19. Mihara H, Ohnari K, Hachiya M, Kondo S, Yamada K. Cervical myelopathy caused by C3-C4 spondylosis in elderly patients: a radiographic analysis of pathogenesis. *Spine (Phila Pa 1976)* 2000;25:796-800.
 20. Hayashi H, Okada K, Hashimoto J, Tada K, Ueno R. Cervical spondylotic myelopathy in the aged patient: a radiographic evaluation of the aging changes in the cervical spine and etiologic factors of myelopathy. *Spine (Phila Pa 1976)* 1988;13:618-25.
 21. Chiba K, Ogawa Y, Ishii K, et al. Long-term results of expansive open-door laminoplasty for cervical myelopathy: average 14-year follow-up study. *Spine (Phila Pa 1976)* 2006;31:2998-3005.
 22. Seichi A, Takeshita K, Ohishi I, et al. Long-term results of double-door laminoplasty for cervical stenotic myelopathy. *Spine (Phila Pa 1976)* 2001;26:479-87.